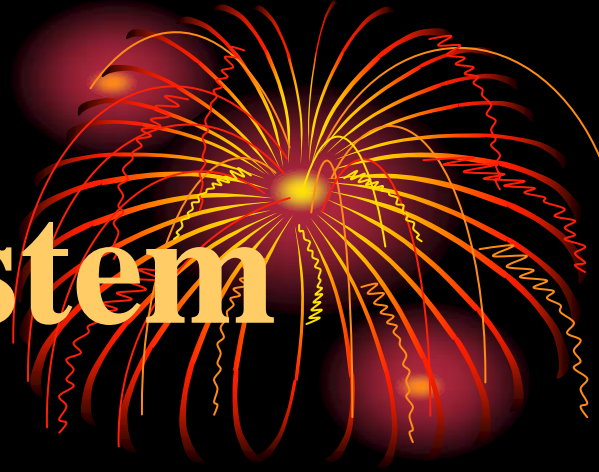

Respiratory system



Department of Histology and
Embryology of Jilin university

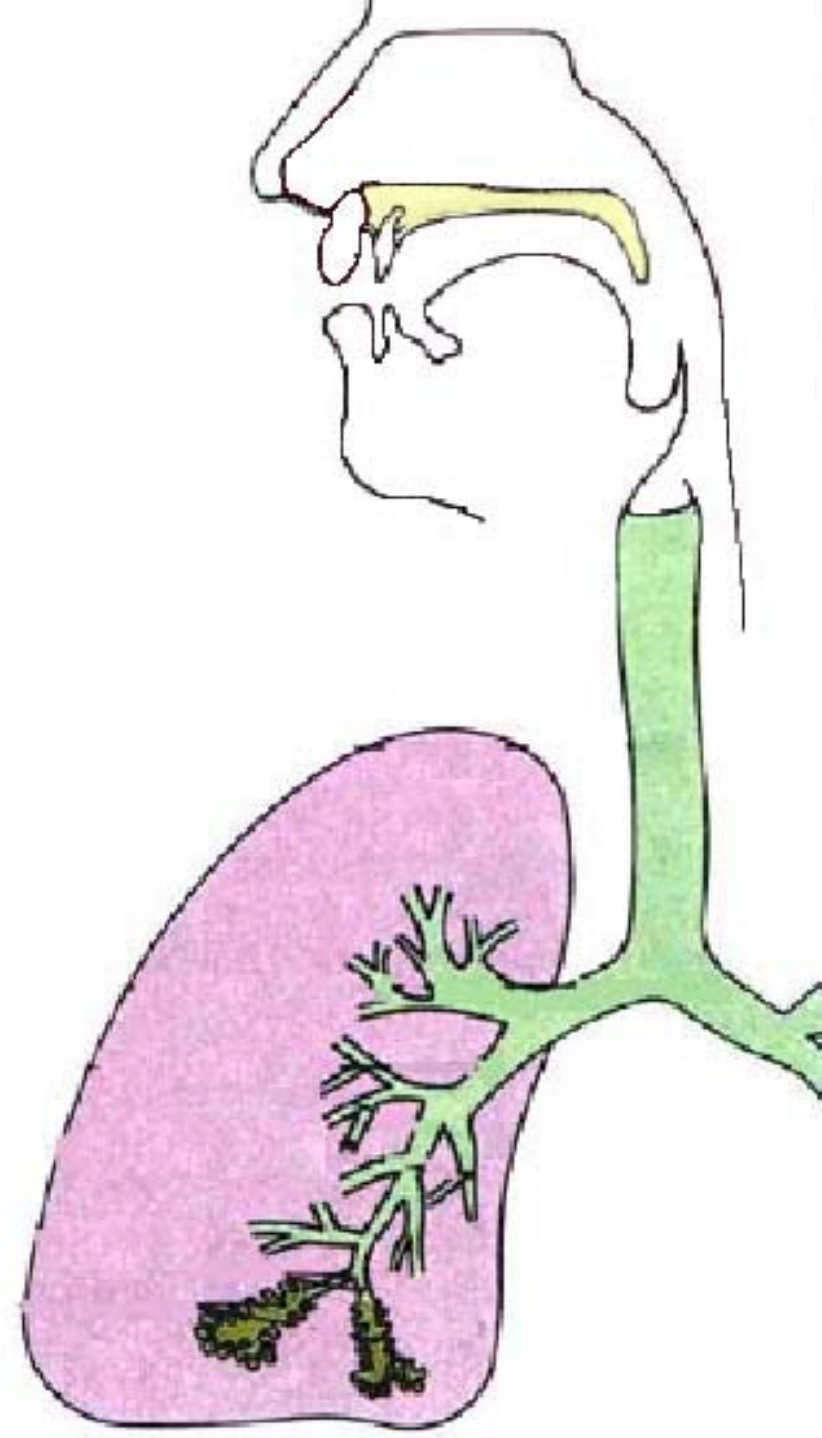
----Jiang Wenhua

1. General description

- the nose, the pharynx, the larynx,
the trachea, bronchus, lung

- Function: inspiring oxygen,
expiring carbon dioxide

The lung synthesises
many materials



2. Trachea and bronchi

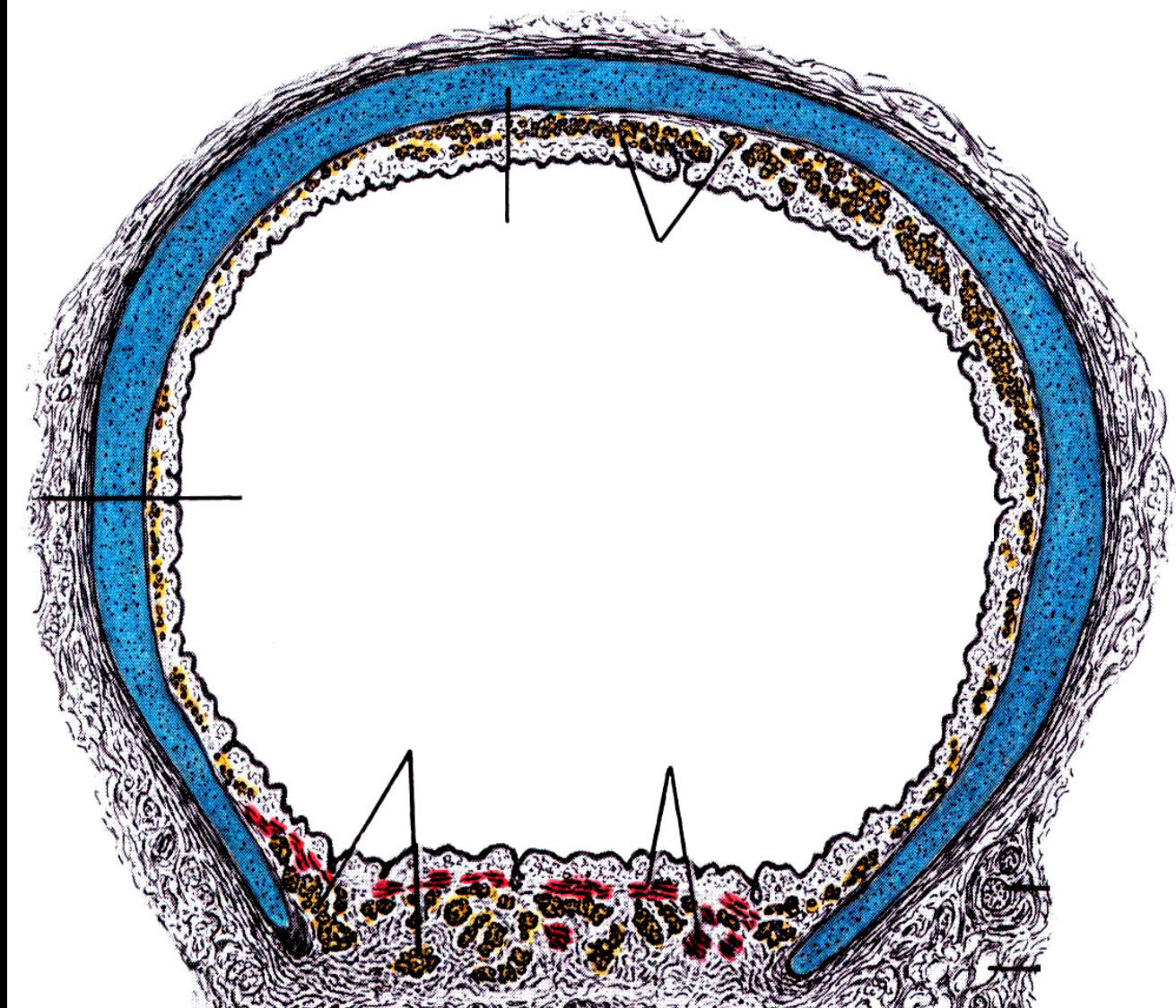
General structure

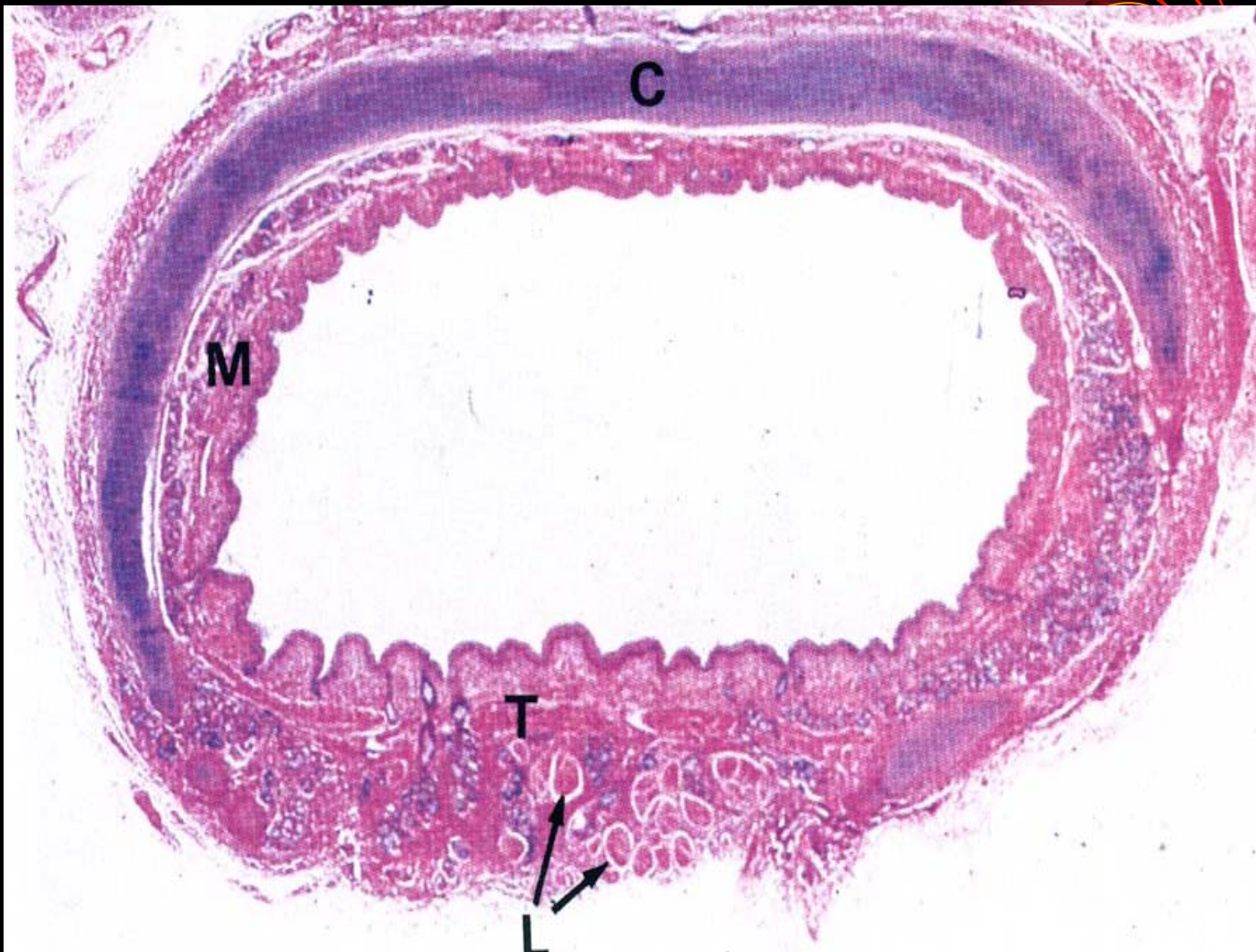


mucosa

submucosa

adventitia

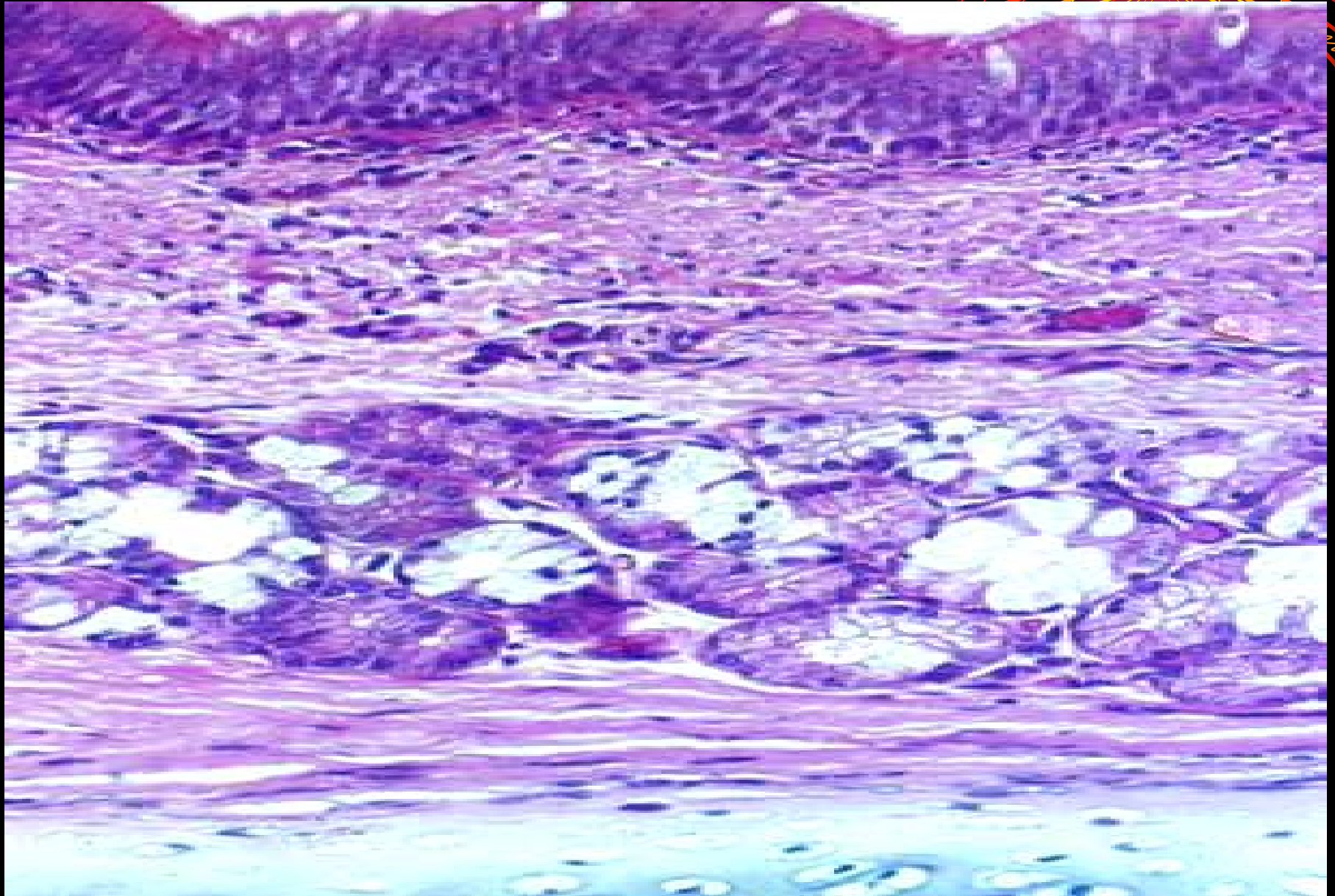




The trachea is a thin-walled tube about 11 centimeters long and 2 centimeters in diameter, with a somewhat flattened posterior shape. The wall of the trachea is composed of three layers: mucosa, submucosa, and adventitia

2.1 mucosa

2.1.1 pseudostratified ciliated columnar epithelium

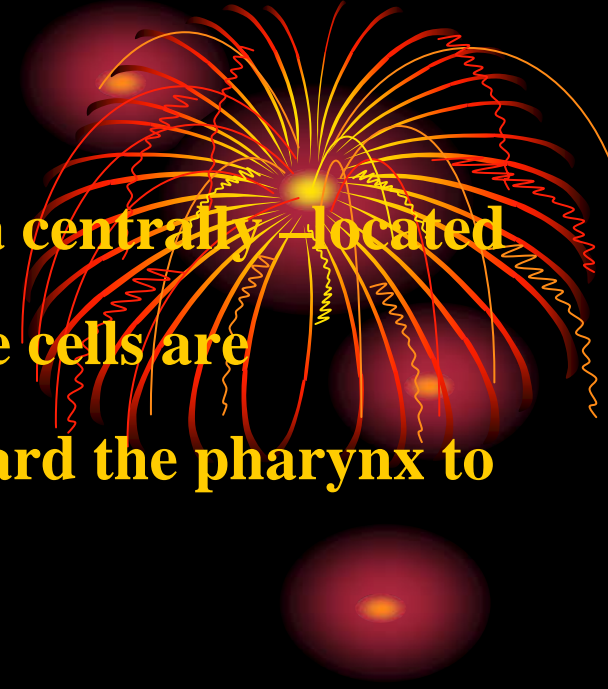

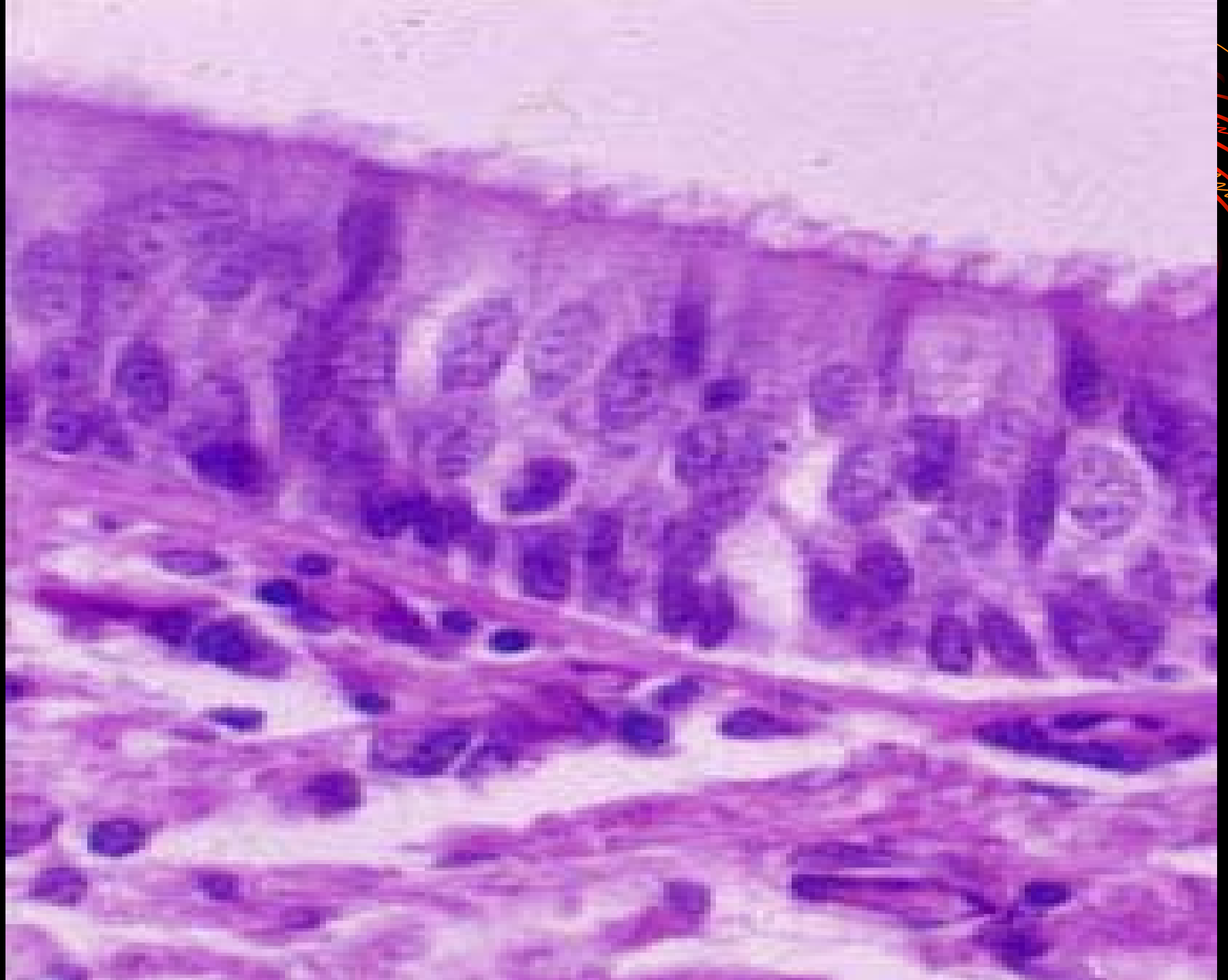
2.1.1.1 ciliated columnar cells

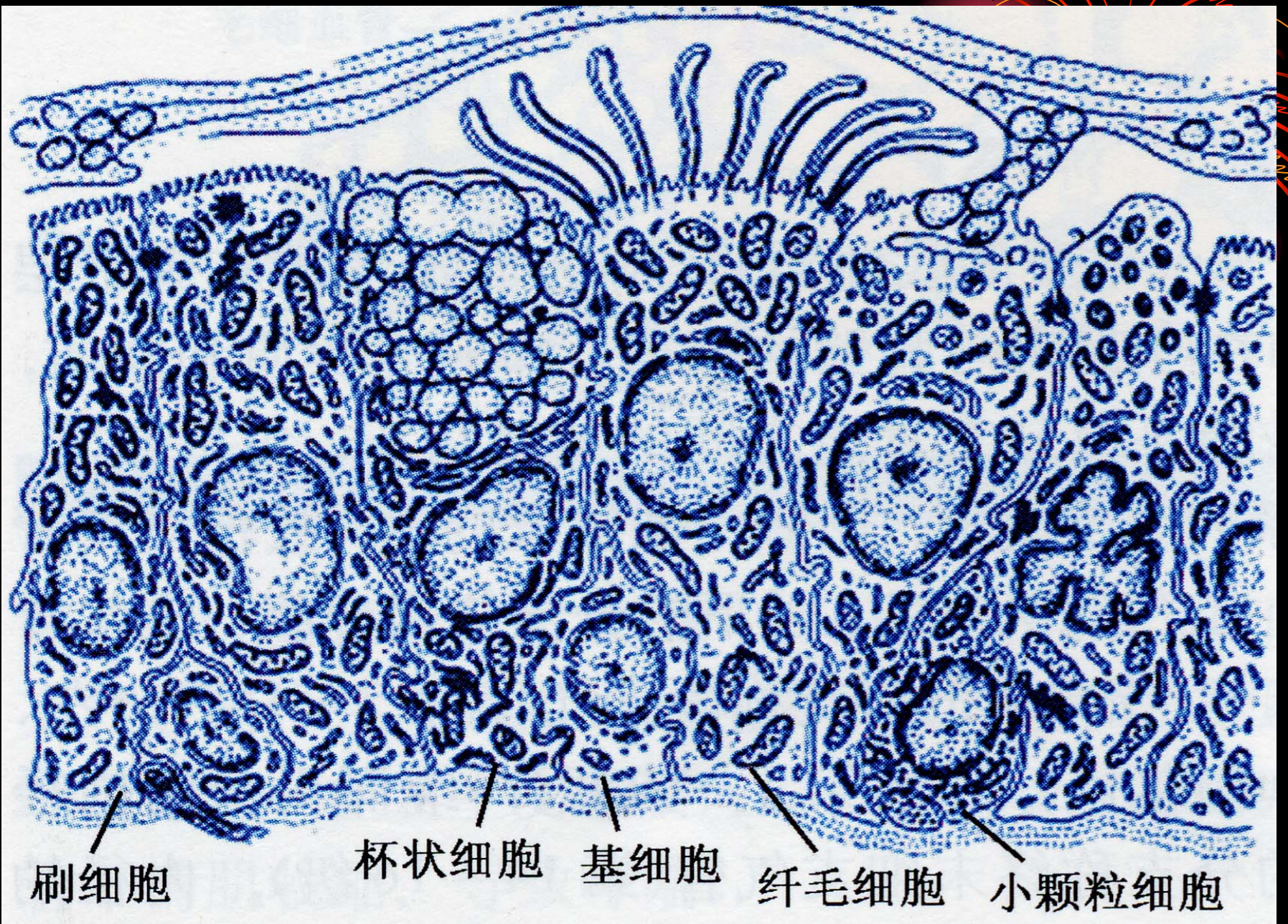
These cells are columnar in shape with a centrally –located oval –shaped nucleus, on the free surface of the cells are microvilli and cilia, which regularly sweep toward the pharynx to remove inspired dust particles

2.1.1.2 brush cells


These cells are columnar in shape with a round or oval –shaped nucleus located in the basal portion. on the free surface the microvilli are arranged into the shape of a brush. These cells are considered to be a type of under-developed ciliated columnar cell



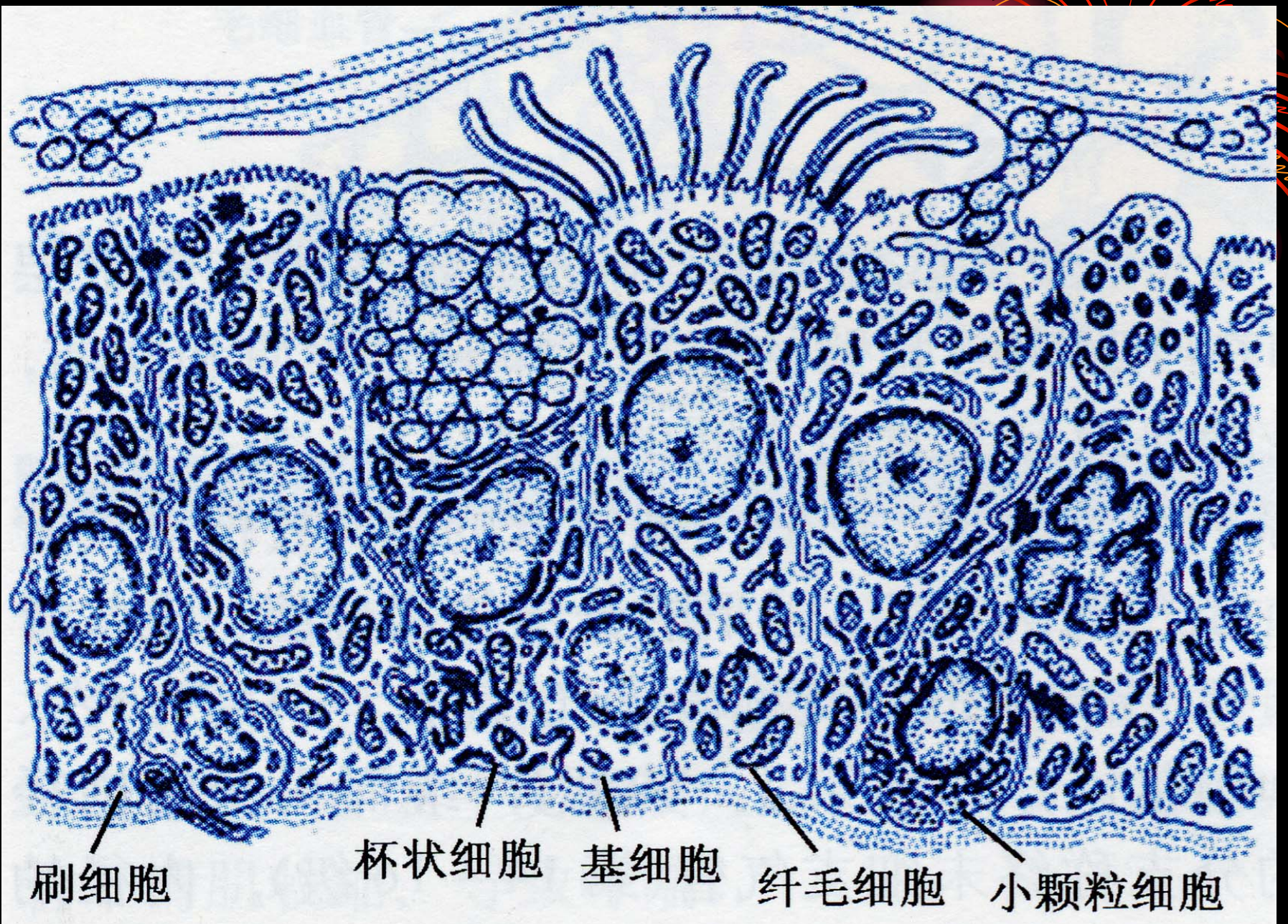




Schematic drawing of the trachea mucosa



Scanning electron micrographs of the surface of mucosa



Schematic drawing of the trachea mucosa



2

1

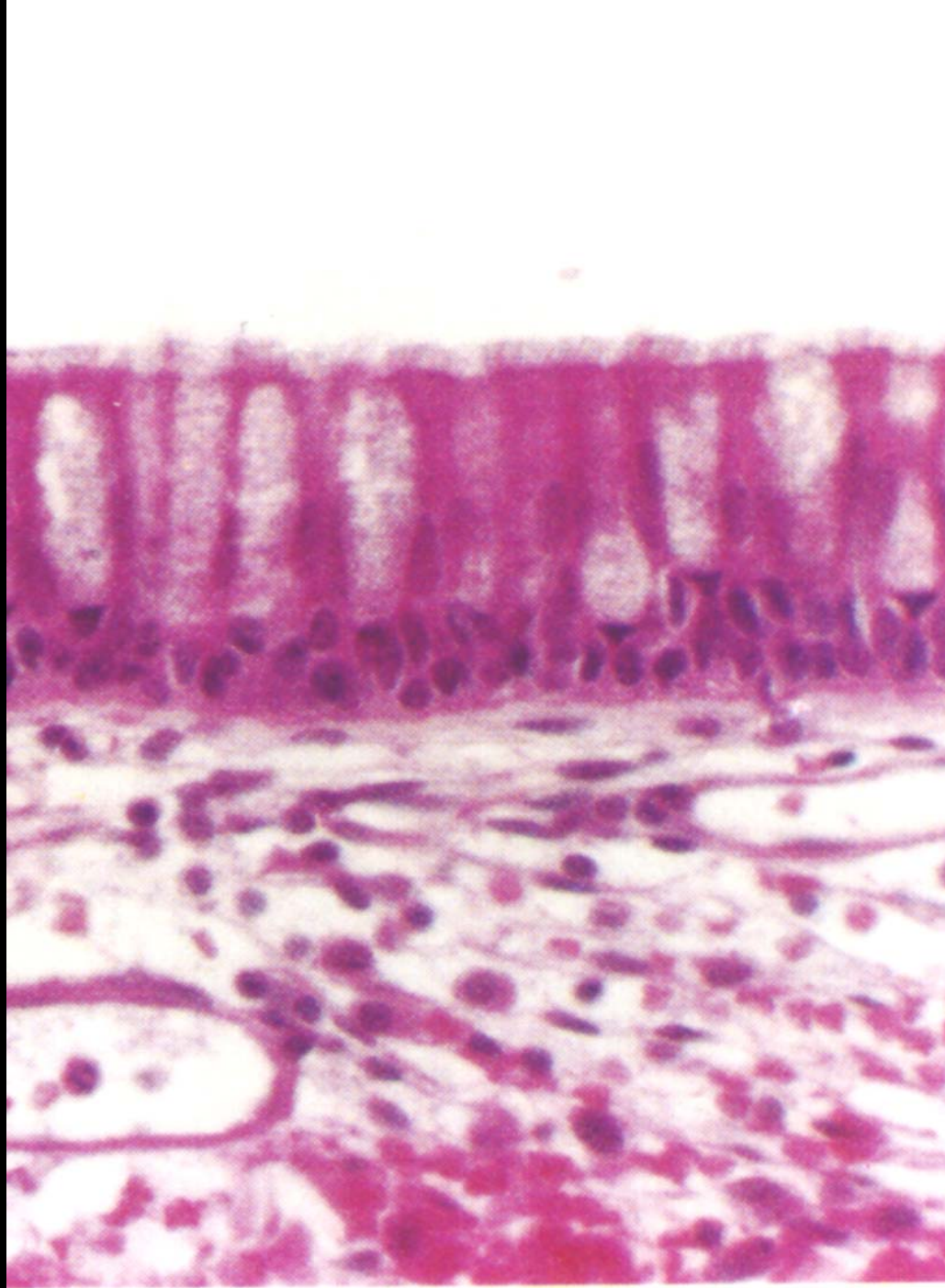
3

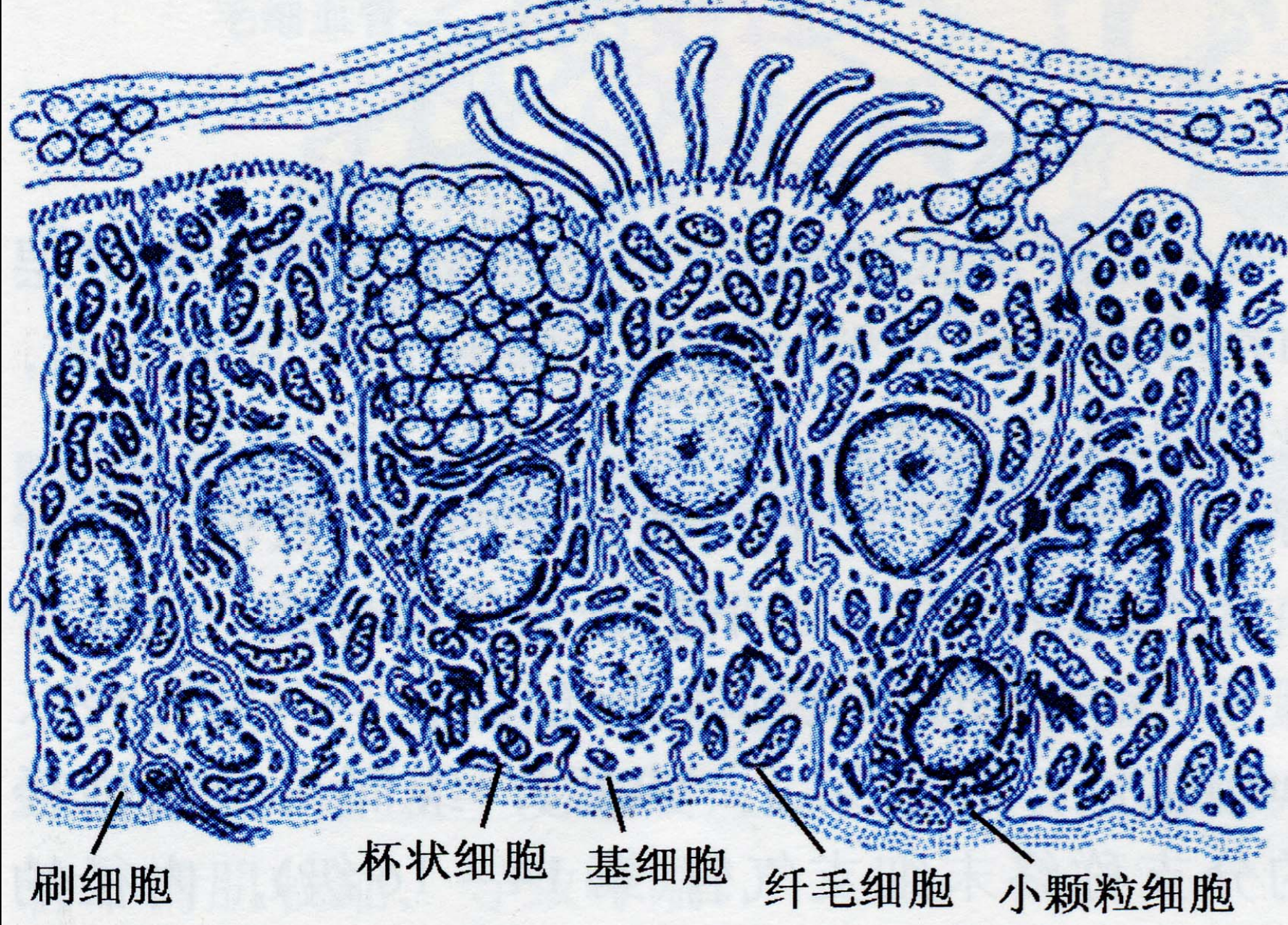
2.1.1.3 goblet cells

secrete mucus to

lubricate and protect

the epithelium





Schematic drawing of the trachea mucosa



2

1

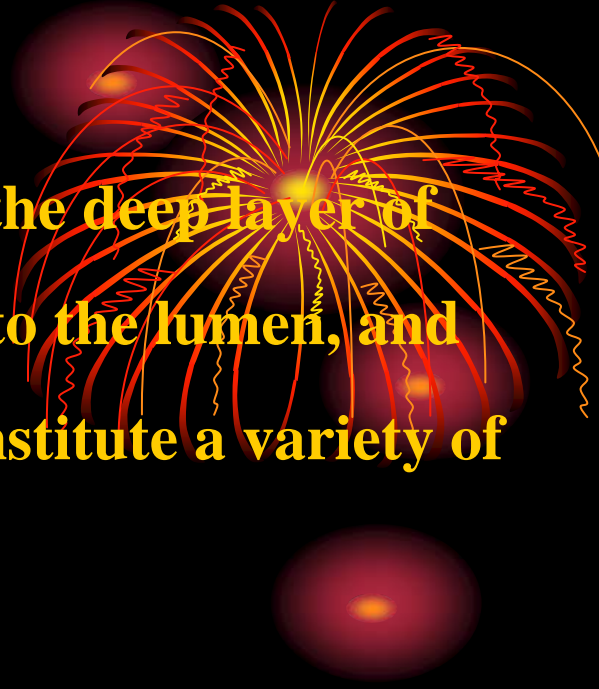
3

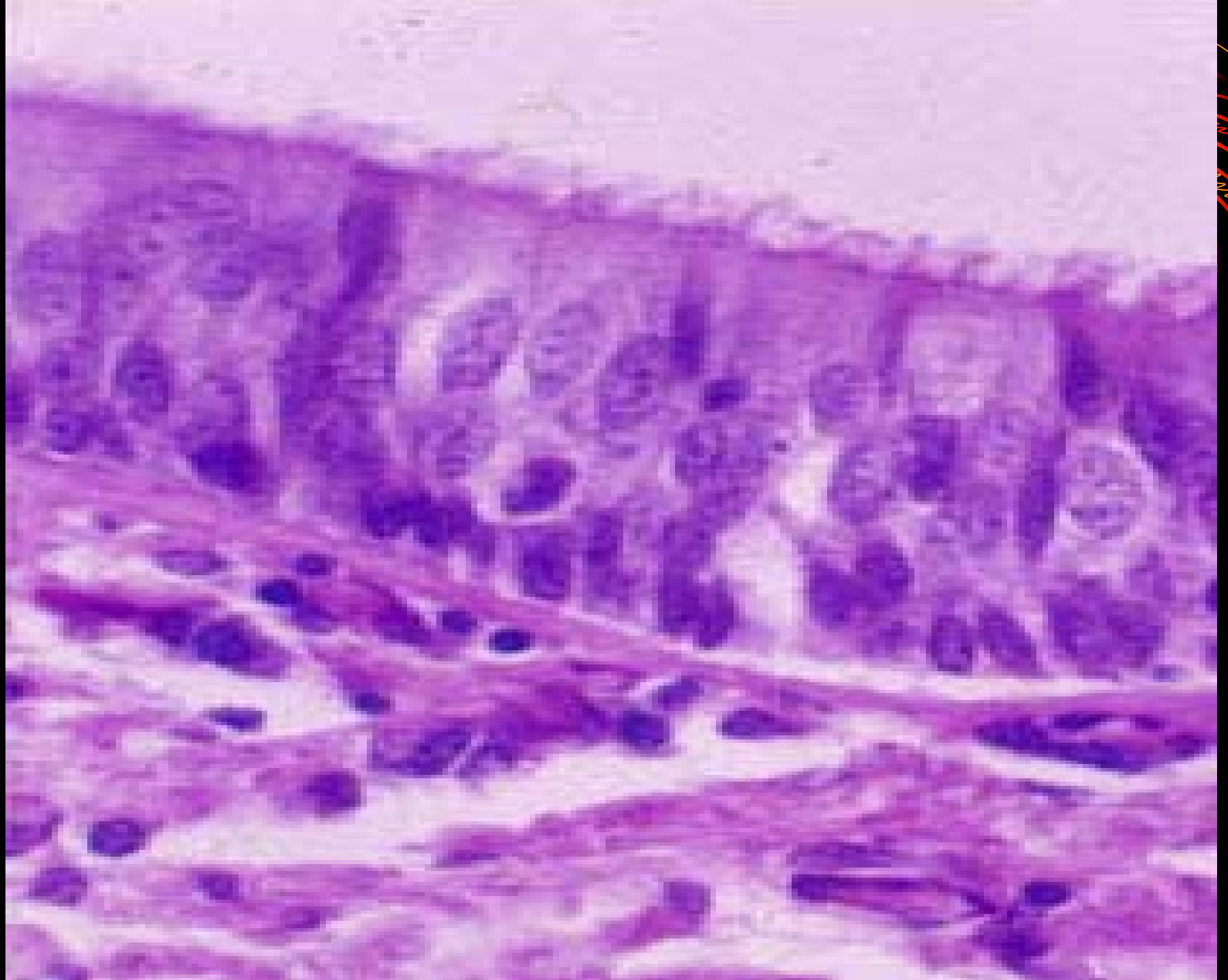
2.1.1.4 basal cells

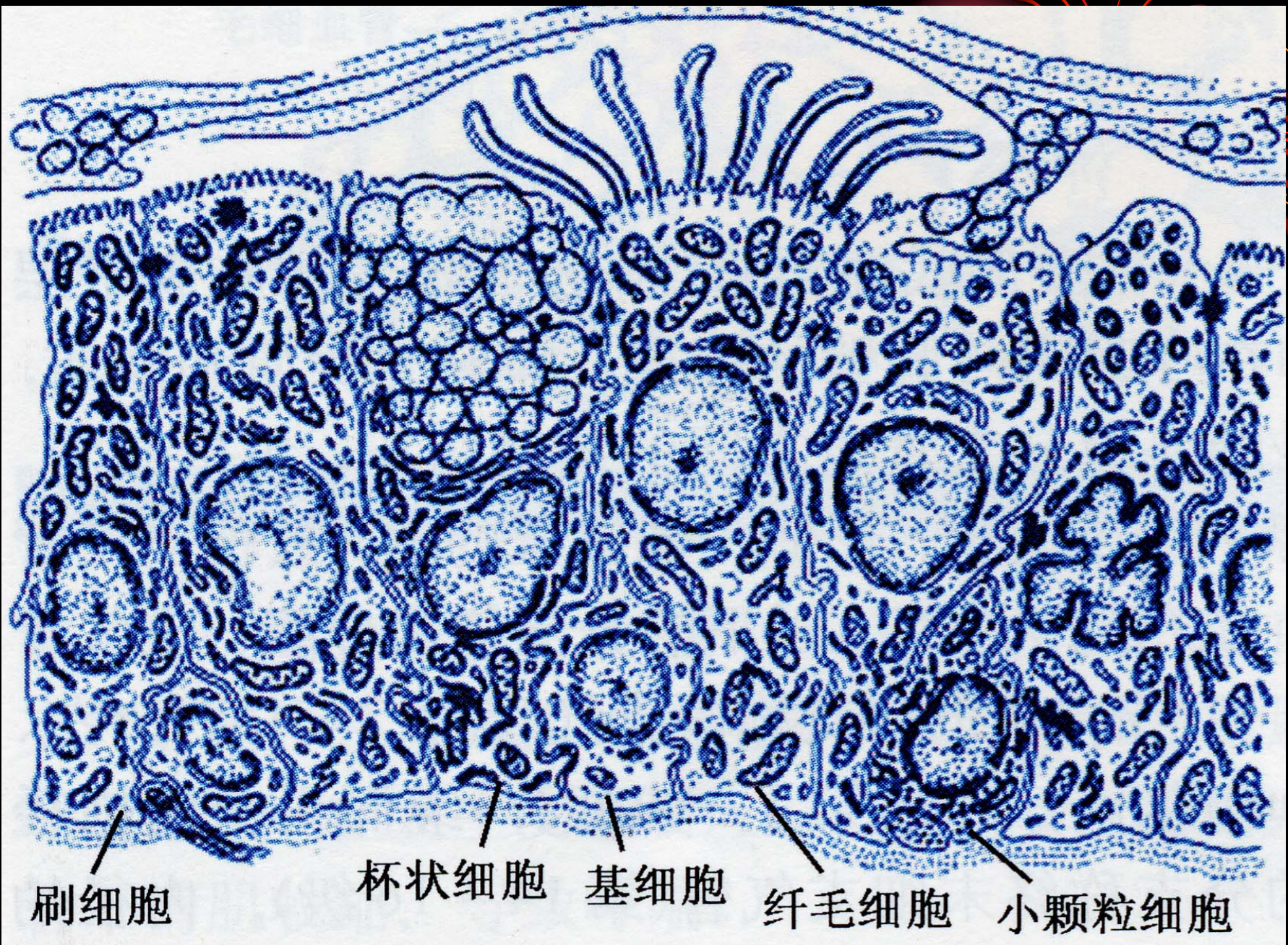
These cells are cone –shaped and situated in the deep layer of the epithelium. Their apices are not exposed to the lumen, and their nuclei are round in shape, such cells constitute a variety of undifferentiated cells

2.1.1.5 small granular cells

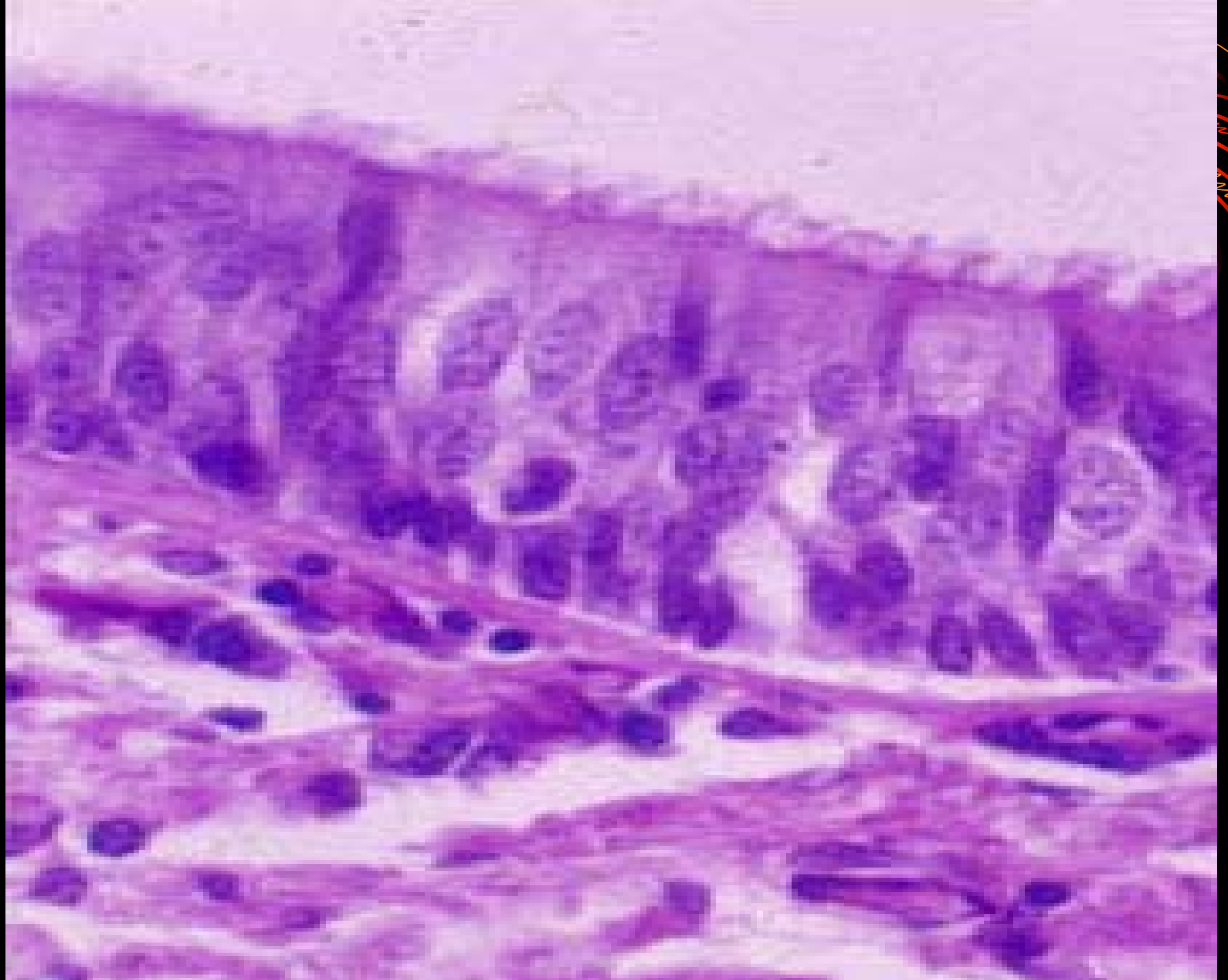
These cells are a kind of endocrine cells . They are cone-shaped and located at the base of the epithelium, and their nucli are oval or triangular in shape. A large number of membrane –bound granules with a central dense core are found in the cytoplasm. These cells secrete 5-hydroxytryptamine and polypeptide

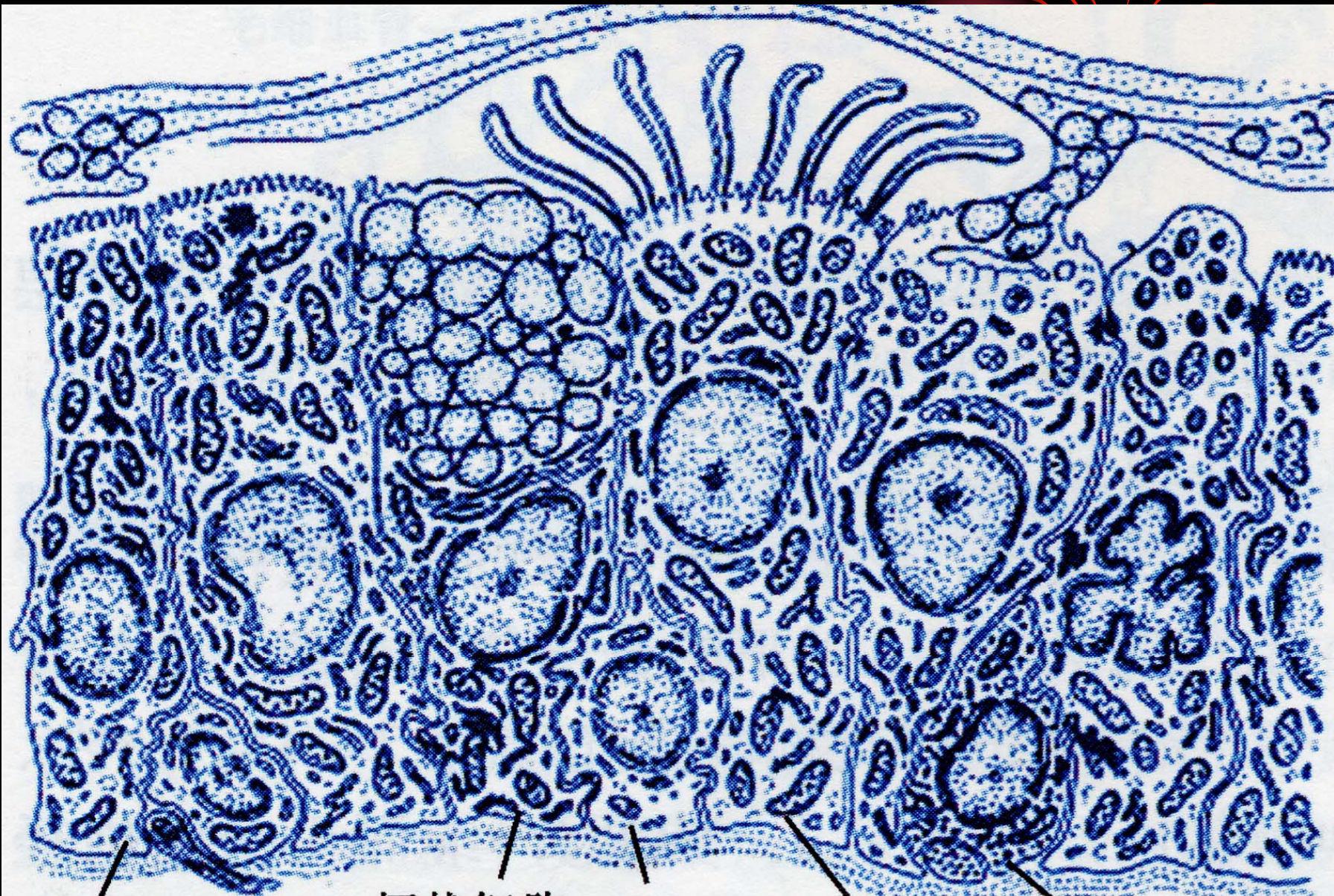






Schematic drawing of the trachea mucosa





刷细胞

杯状细胞

基细胞

纤毛细胞

小颗粒细胞

Schematic drawing of the trachea mucosa

2.1.2 tunica propria

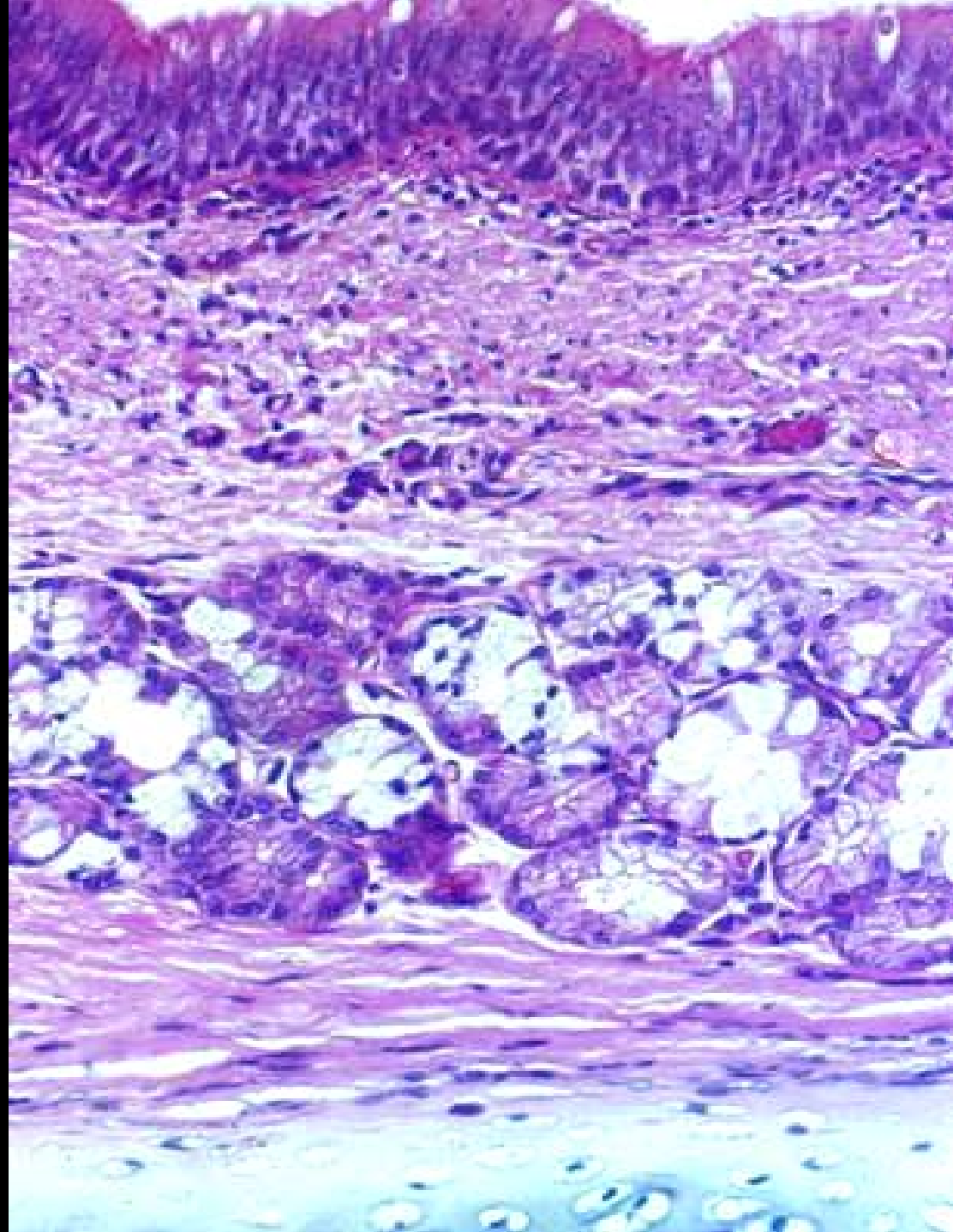
**a relatively thin layer of
connective tissue**

many elastic fibres,

a few lymphocytes


plasma cells

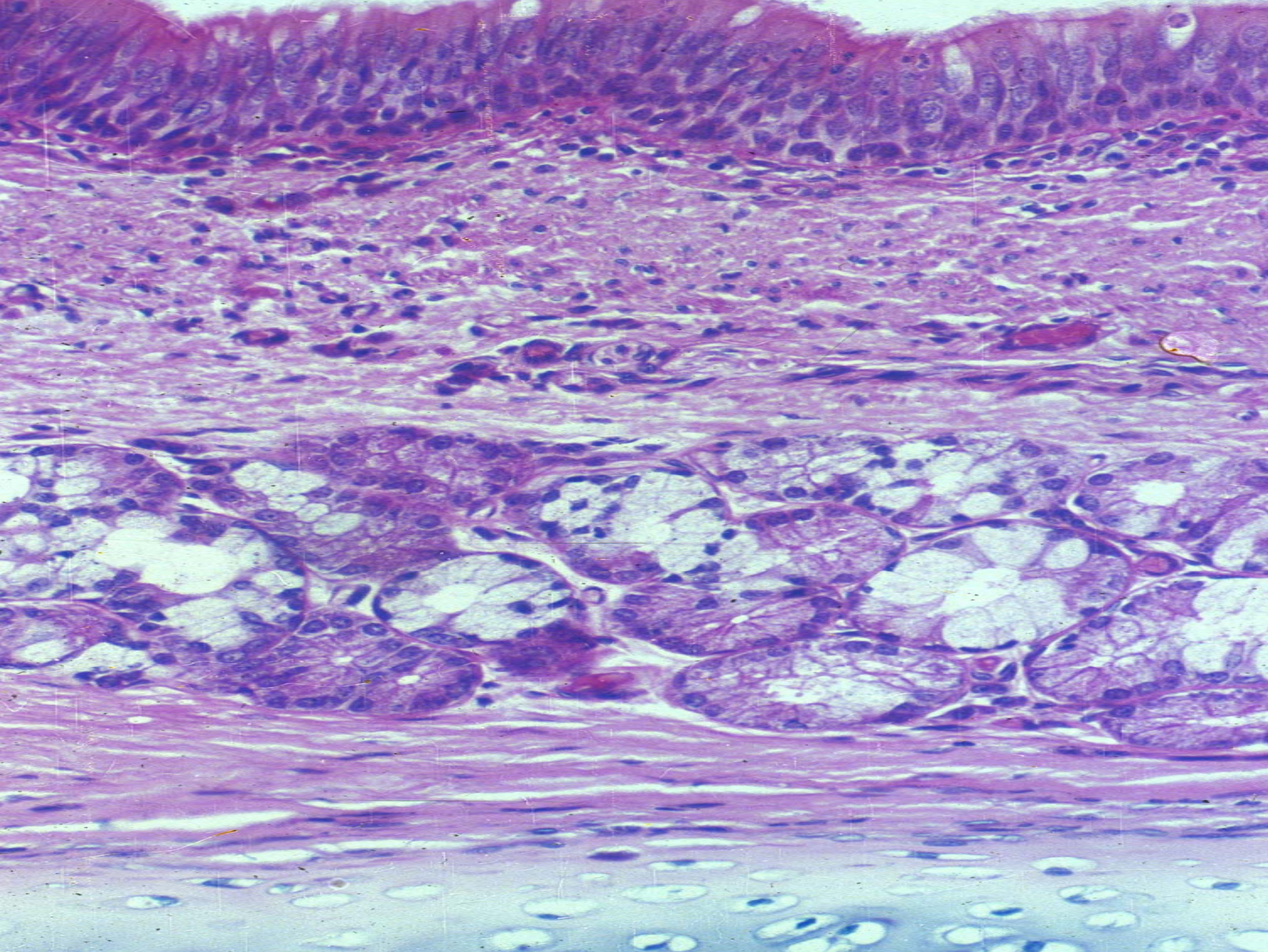
small sero-mucous glands.



2.2 submucosa

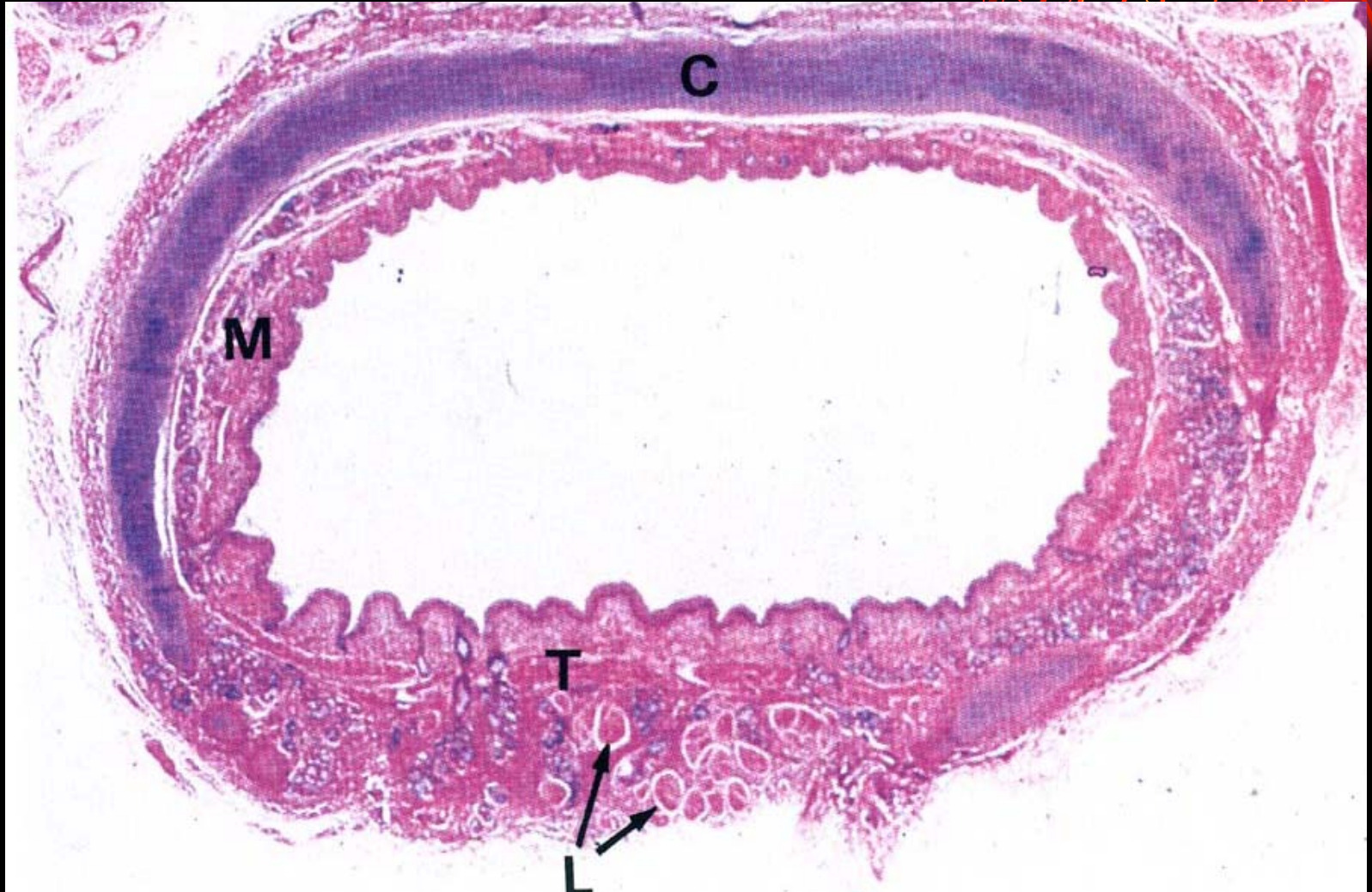
The submucosa is composed of loose connective tissue and contains blood vessels, lymphatics and numerous mixed glands, these glands are sero-mucous. the glandular ducts, lined with a simple columnar epithelium, pass through the tunica propria and open on to the free surface of the epithelium.the boundary between the lamina propria and submucosa is not obvious

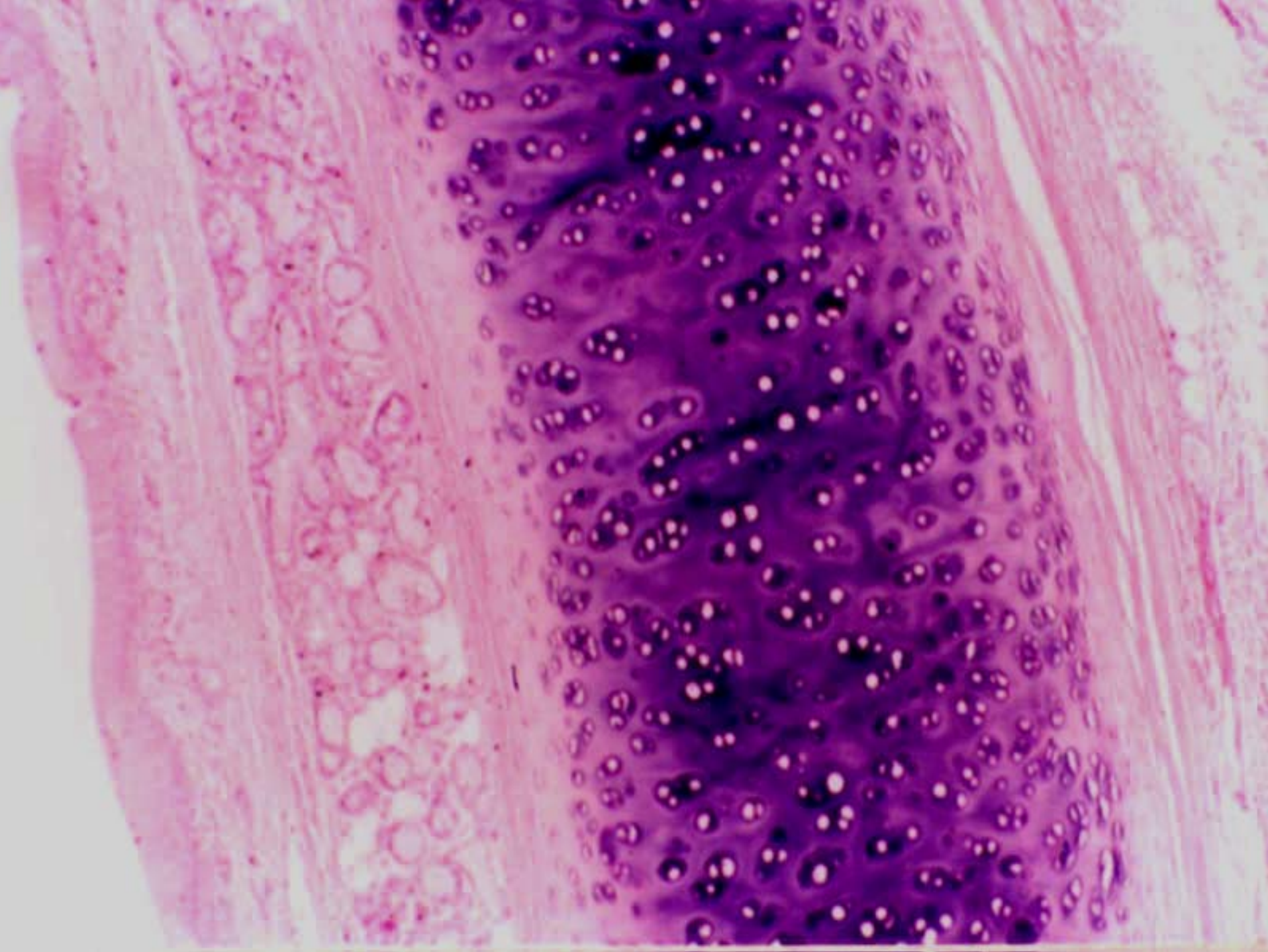


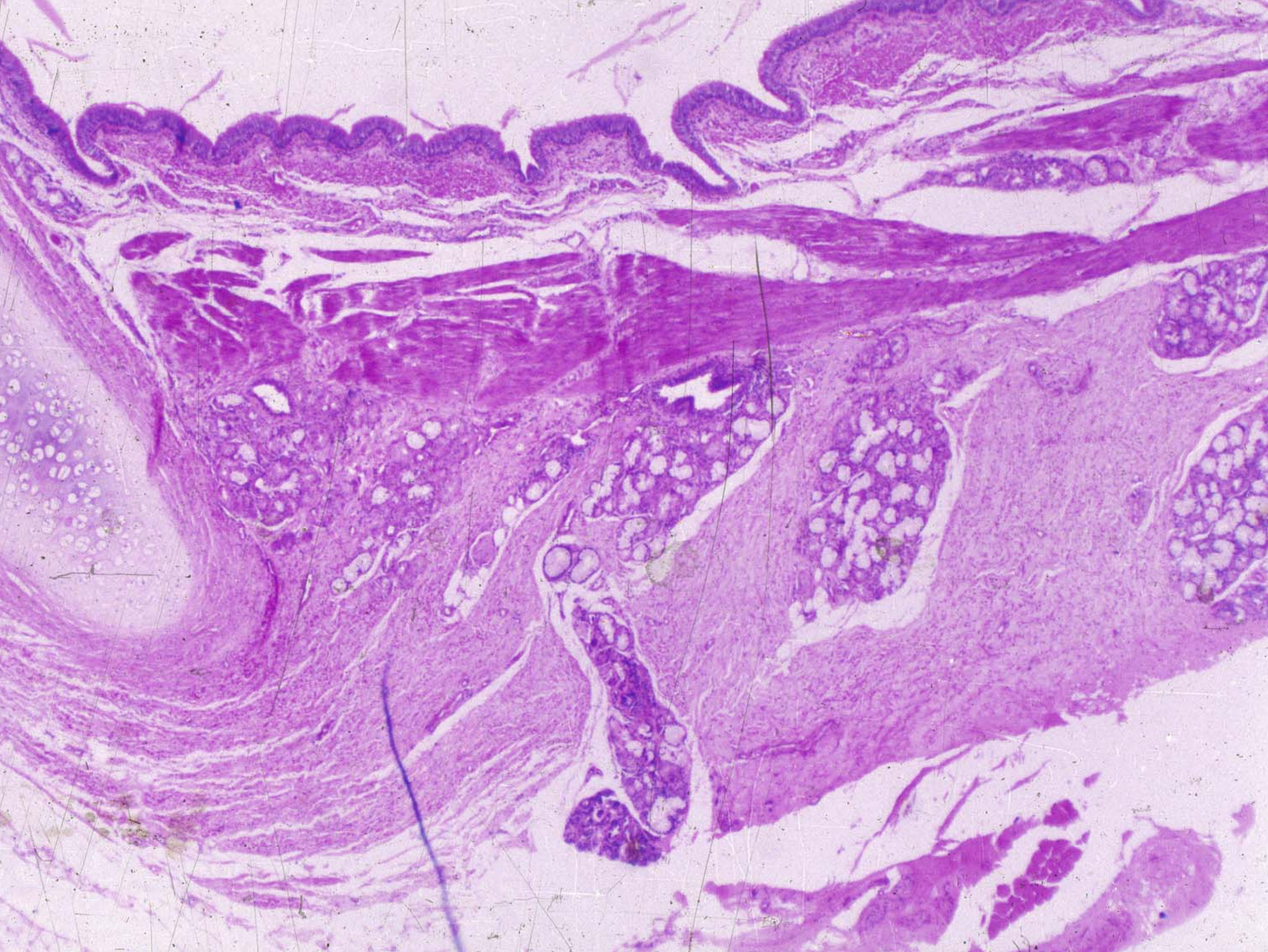


2.3 adventitia

Is constructed of the C-shaped rings of hyaline cartilage, smooth muscle, and dense connective tissue, supports the tracheal and bronchial lumen patent.







3.lung

serosa

parenchyma

interstitium

Conducting portion

Respiratory portion

bronchi

bronchioles

Terminal bronchioles

Respiratory bronchioles

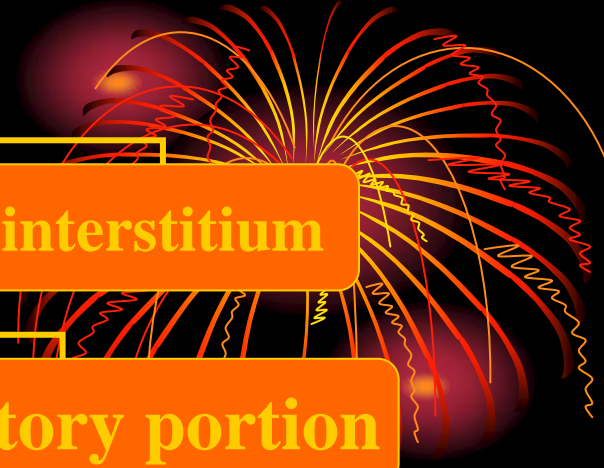Alveolar ducts

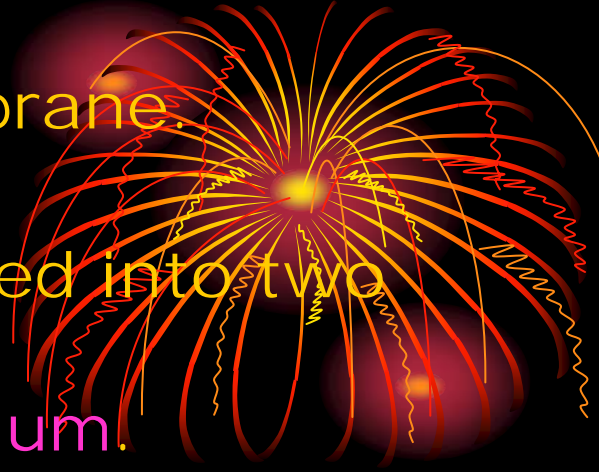Alveolar sacs

alveoli

the passage of air

the exchange of air

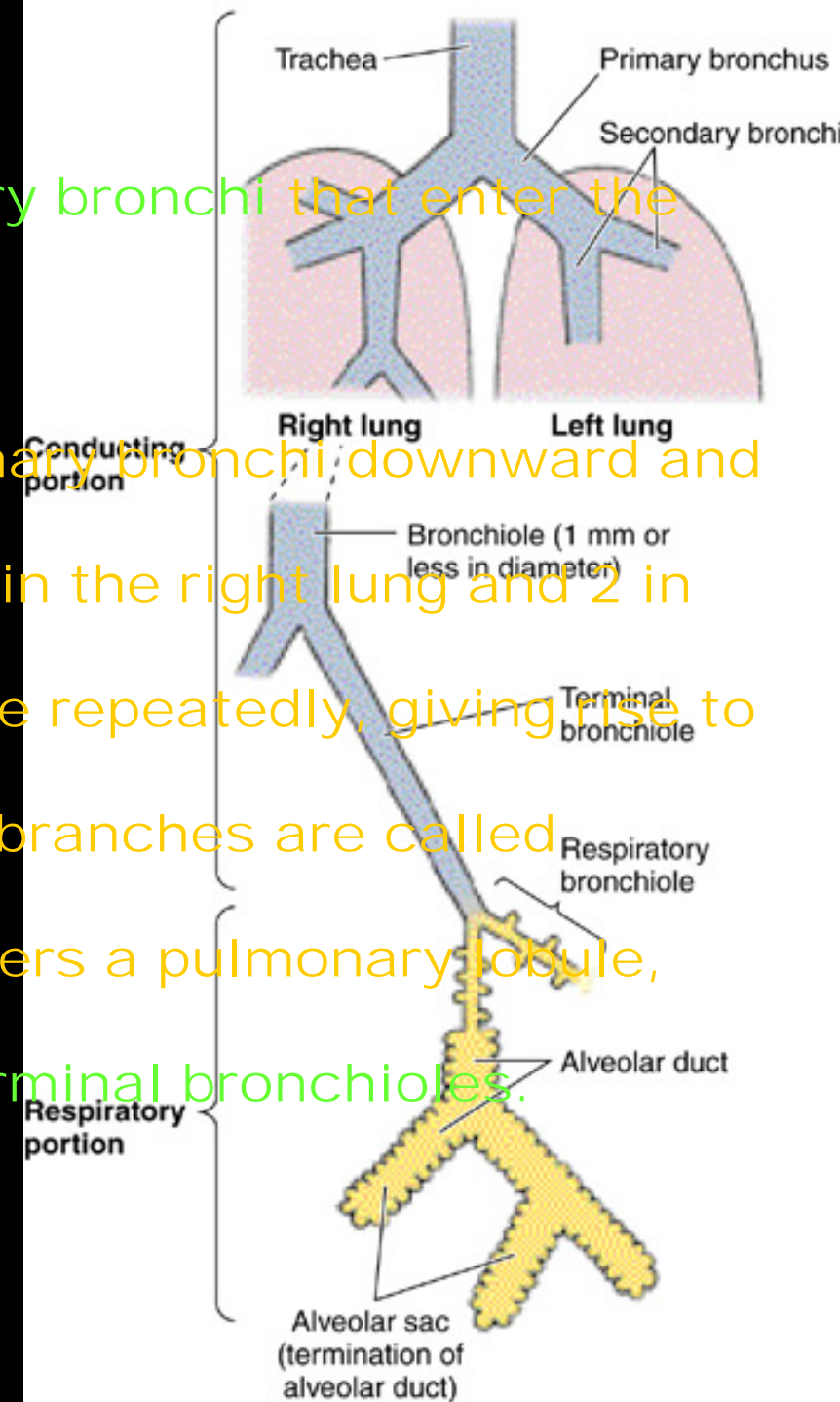




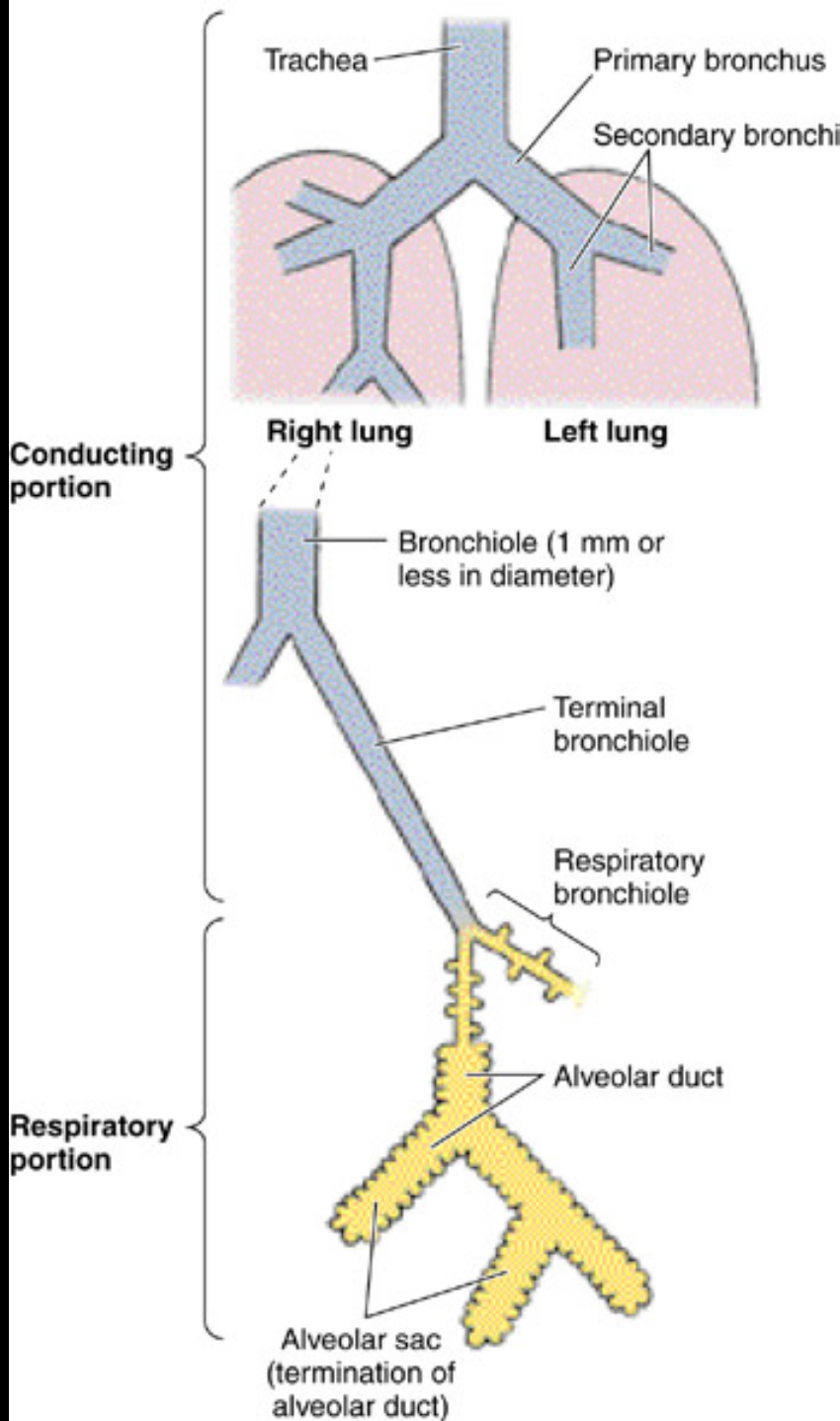


- The lung is covered a serous membrane.
- The structure of lungs can be divided into two portions: parenchyma and interstitium.

parenchyma of lungs is divided into 2 principal portions: A conducting portion, known as bronchial tree, consisting of the bronchi, bronchioles, and terminal bronchioles; and a respiratory portion, consisting of respiratory bronchioles, alveolar ducts, alveolar sacs, and alveoli

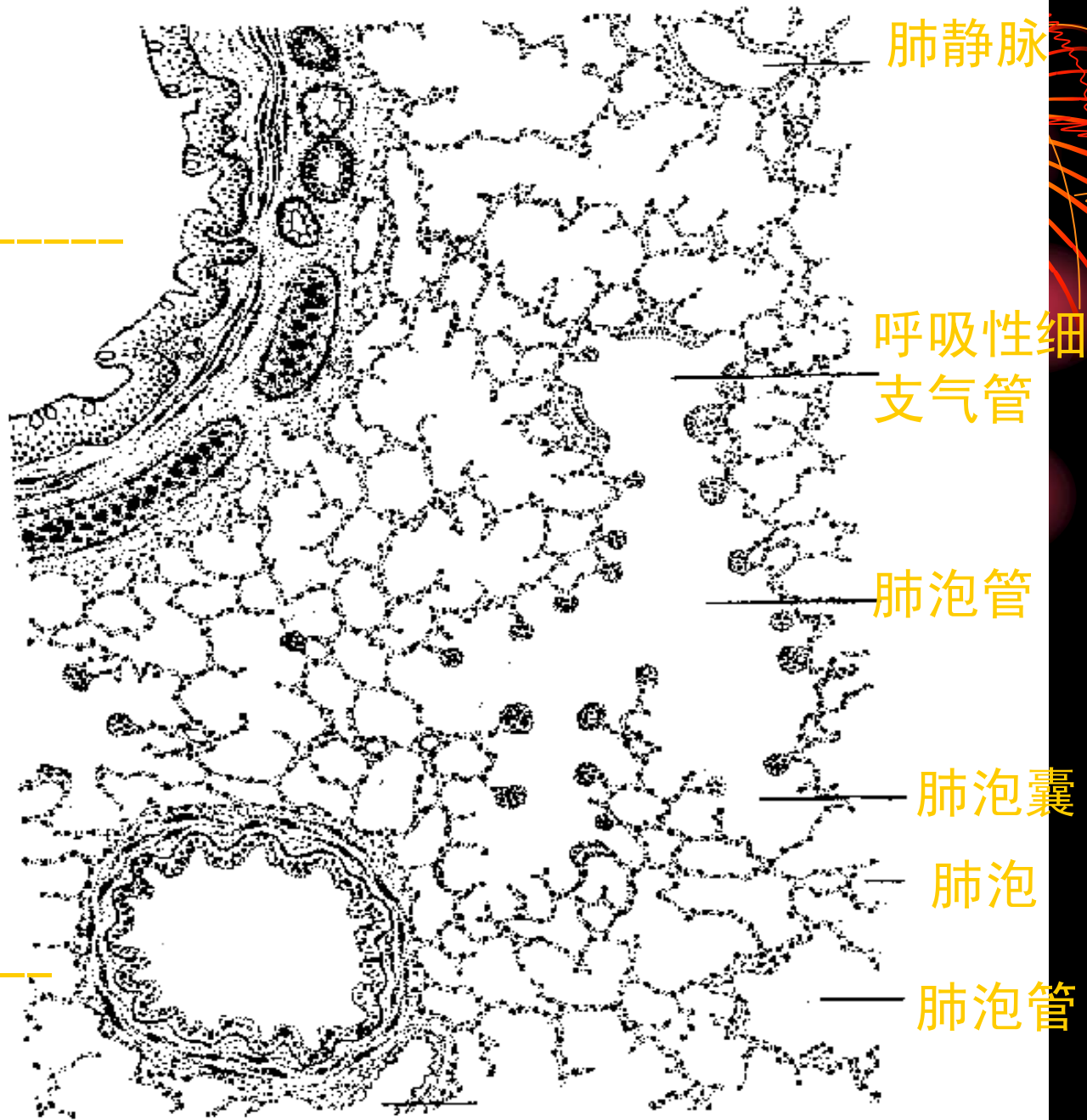
- The trachea divides into 2 primary bronchi that enter the lungs at the hilum.
- After entering the lungs, the primary bronchi divide downward and outward, giving rise to 3 bronchi in the right lung and 2 in the left lung. These bronchi divide repeatedly, giving rise to smaller bronchi, whose terminal branches are called bronchioles. Each bronchiole enters a pulmonary lobule, where it branches to form 5-7 terminal bronchioles.





小支气管

终末细支气管



肺静脉

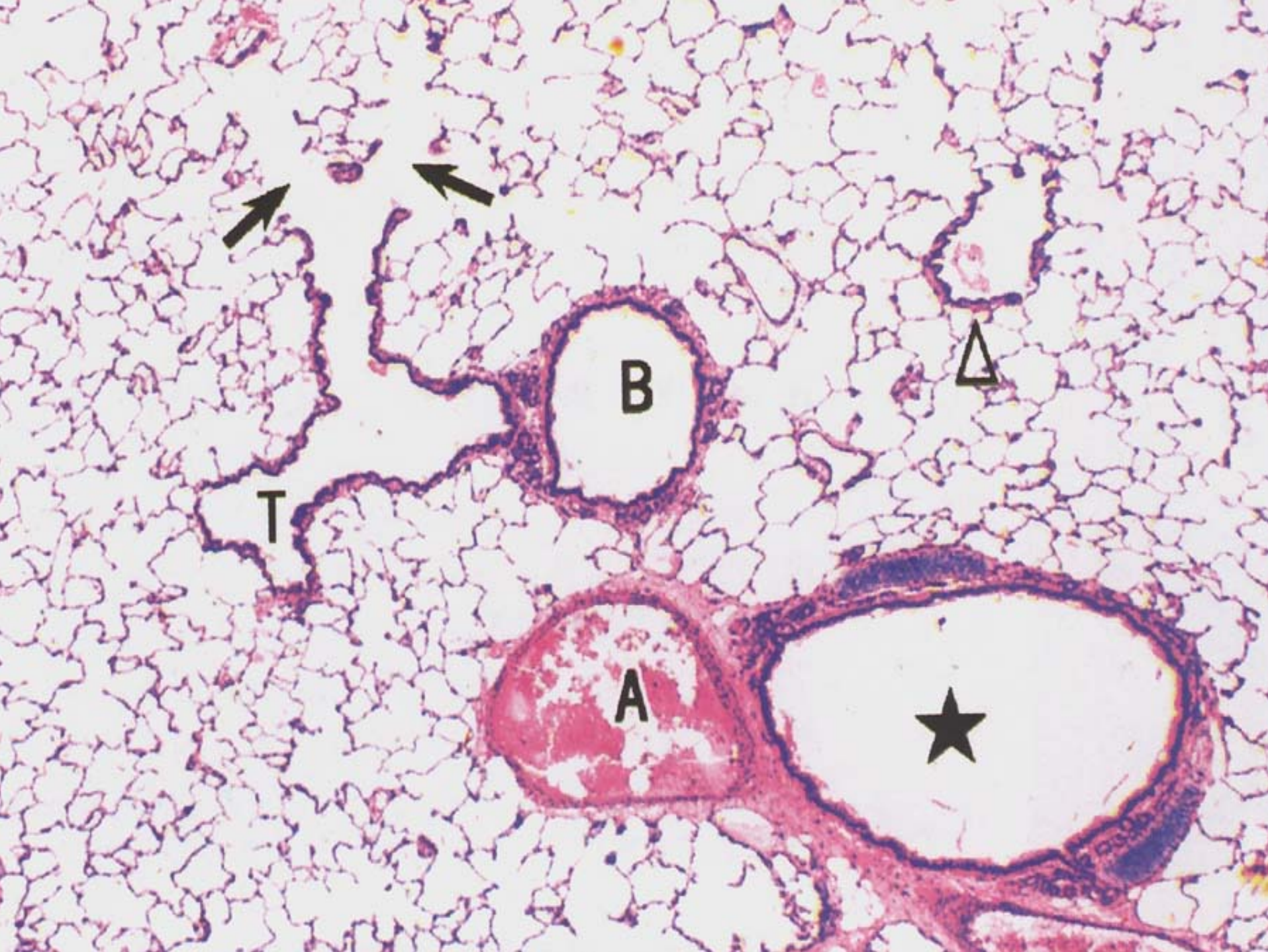
呼吸性细
支气管

肺泡管

肺泡囊

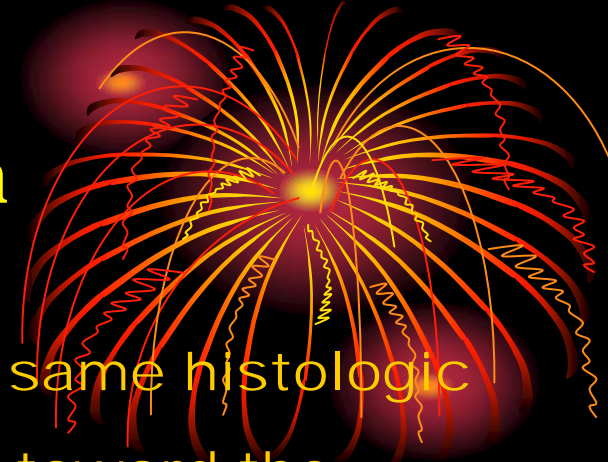肺泡

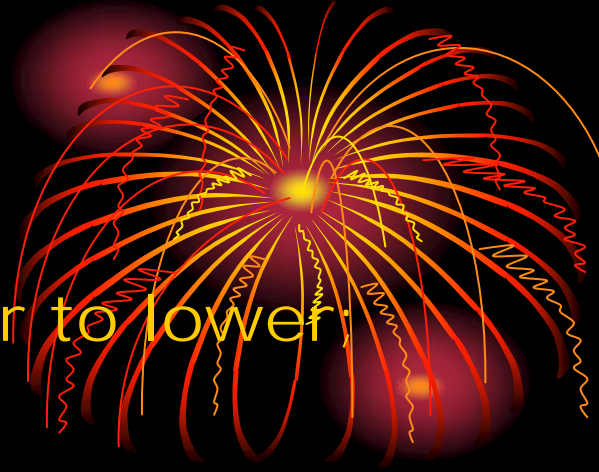肺泡管



3.1 Conducting Portion


- The primary bronchi generally have the same histologic appearance as the trachea. Proceeding toward the respiratory portion, the histologic organization of both the epithelium and the underlying lamina propria becomes simplified. this simplification is gradual; no abrupt transition can be observed between the bronchi and bronchioles. For this reason, the division of the bronchial tree into bronchi, bronchioles, etc, is to some extent artificial.



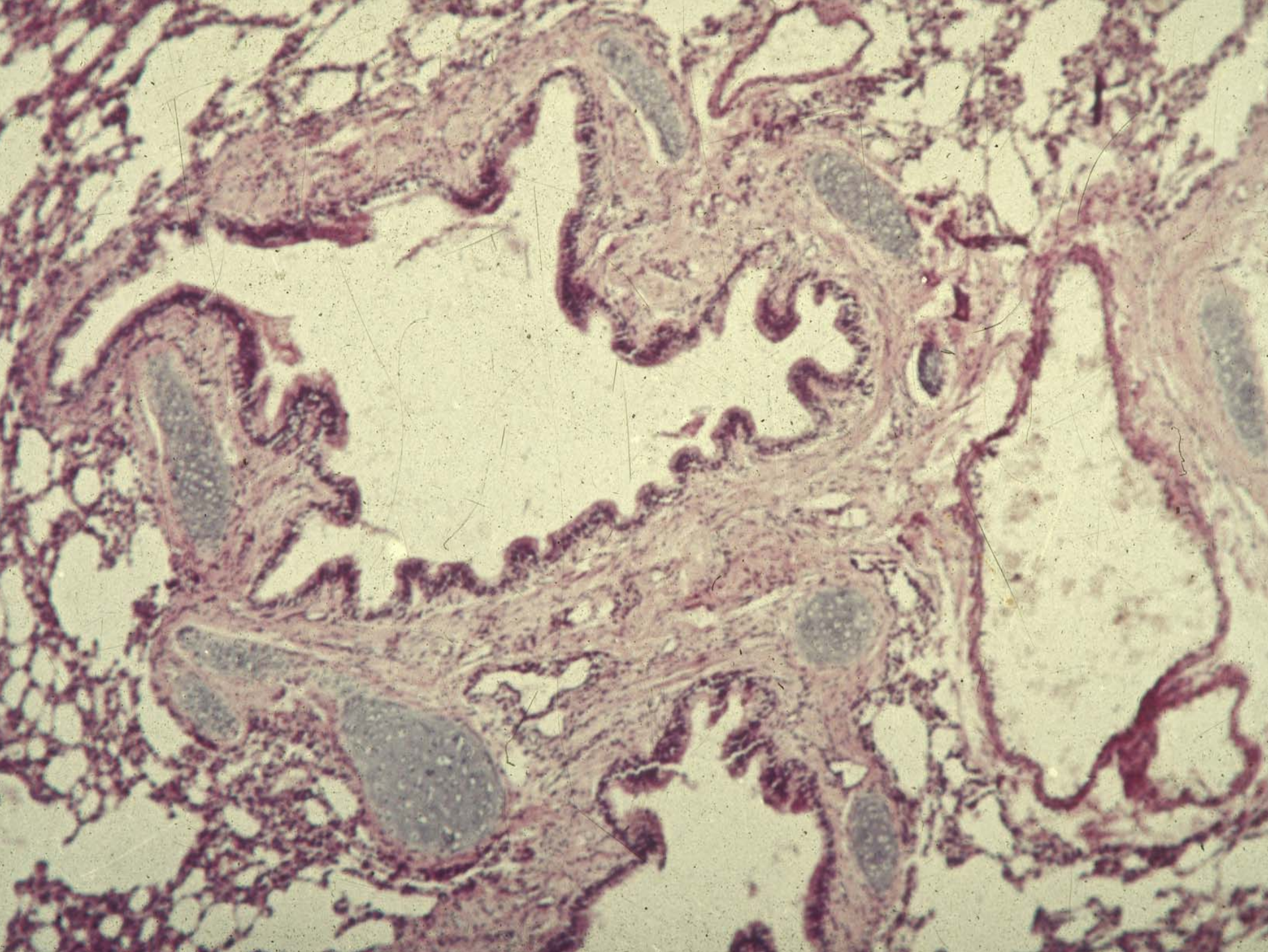


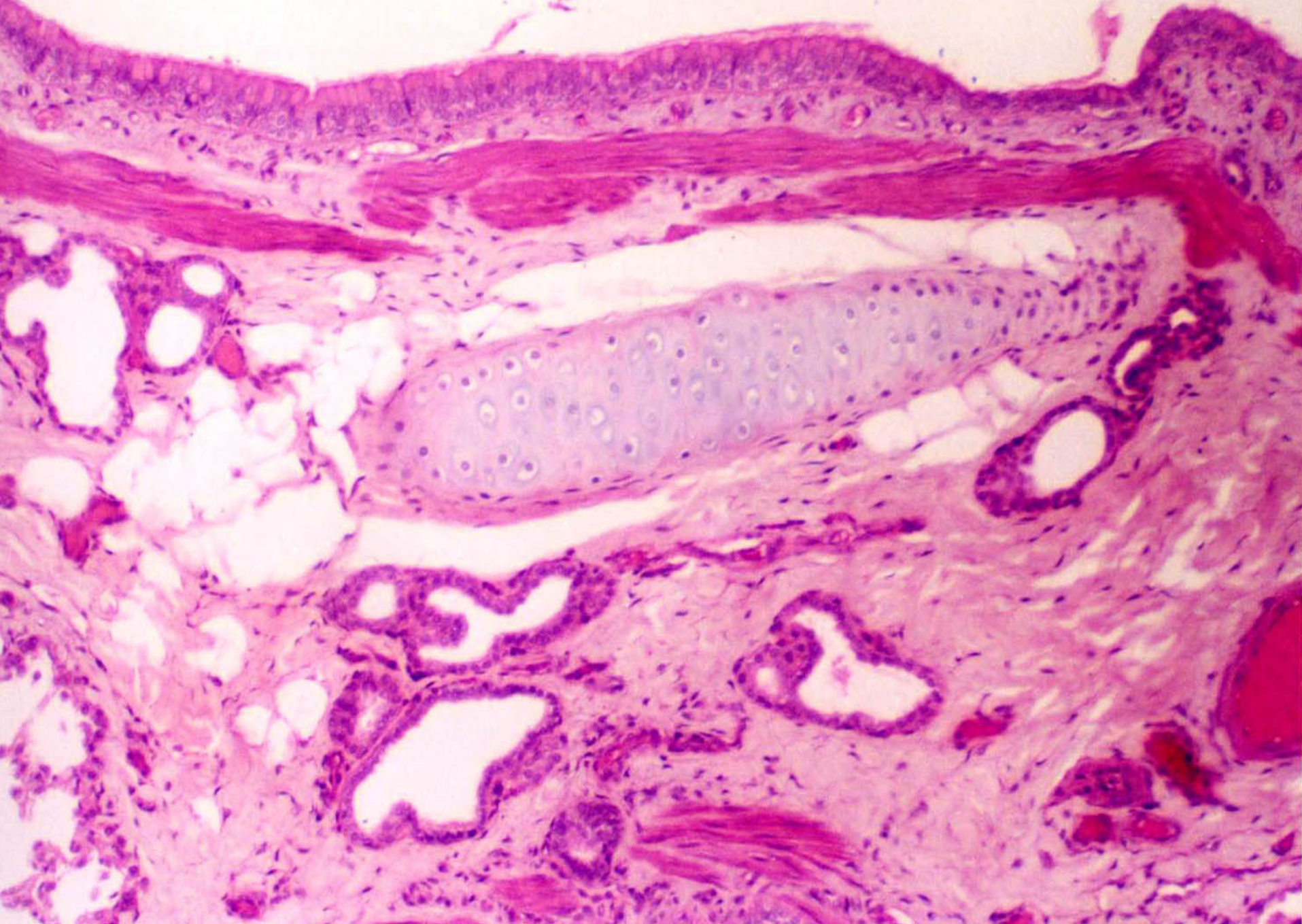
3.1.1 bronchi

- ① The epithelium changes from higher to lower;
decrease of goblet cells
- ② more numerous bunches of smooth muscle cells
in the outer of lamina propria
- ③ Gradual decrease of tracheal glands
- ④ The cartilage changes for pieces of cartilage



- Each primary bronchus branches 9–12 times, with each branch becoming progressively smaller until it reaches a diameter of about 1 mm. the mucosa of the bronchi is structurally similar to the mucosa of the trachea . The bronchial cartilages are more irregular in shape than those found in the trachea; As bronchial diameter decreases, the cartilage rings are replaced with isolated plates, or islands, of hyaline cartilage. Beneath the epithelium, in the bronchial lamina propria, is a smooth muscle layer consisting of crisscrossing bundles of spirally arranged smooth muscle . Bundles of smooth muscle become more prominent near the respiratory zone.






3.1.2 bronchioles

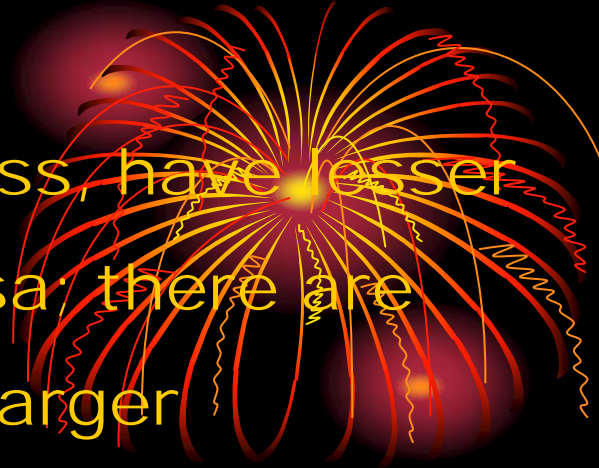With thinner wall, 1mm in diameter

A simple columnar ciliated epithelium

Goblet cells , tracheal glands , cartilage gradually reduce to disappear.

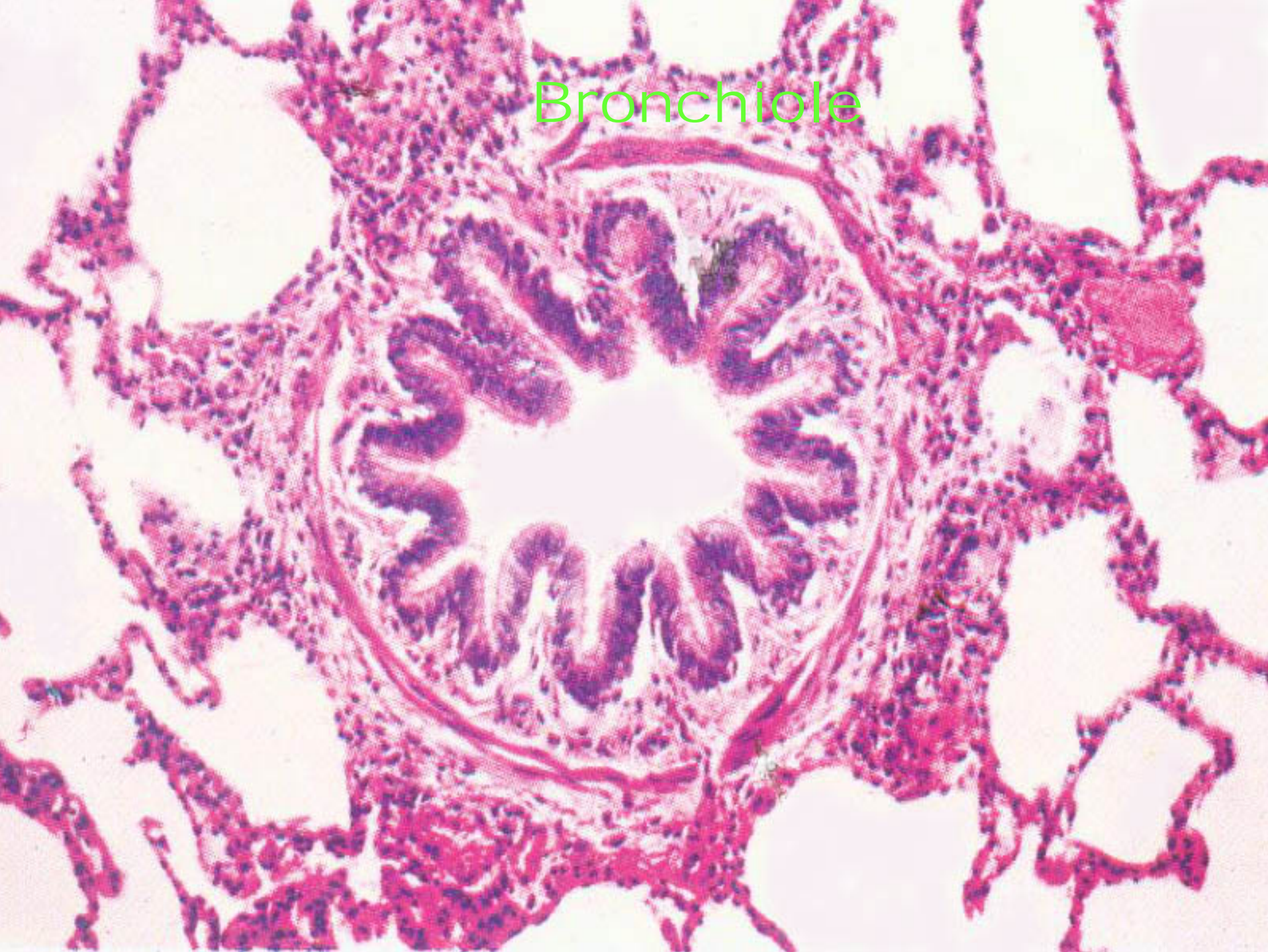
The smooth muscles increase comparatively to form a circular stratum

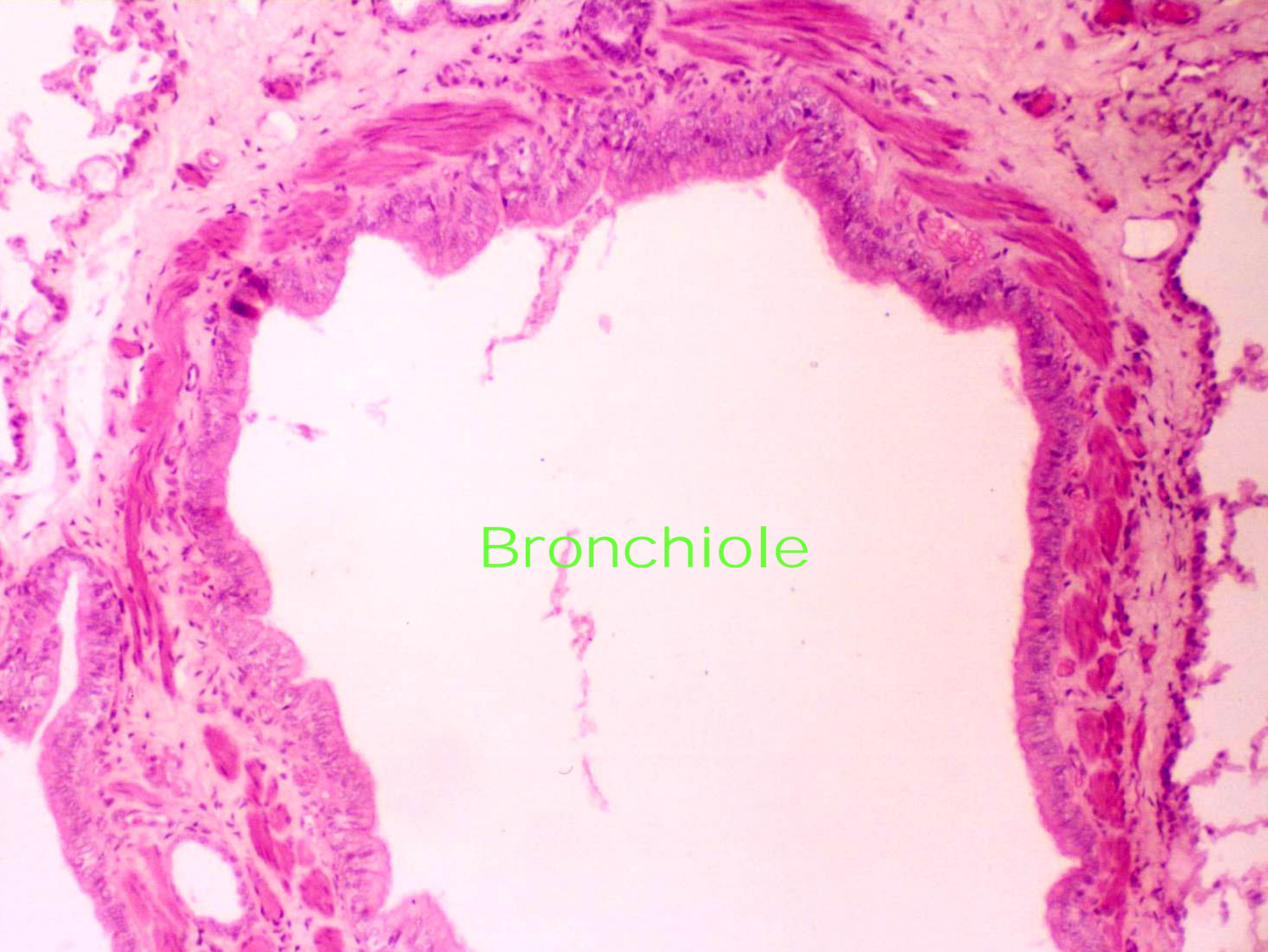



- Bronchioles diameter is 1 mm or less, have lesser cartilage and glands in their mucosa; there are only scattered goblet cells. In the larger bronchioles, the epithelium is pseudostratified ciliated columnar, which decreases in height and complexity to become simple ciliated columnar epithelium in the smaller bronchioles. Bronchiolar lamina propria is composed largely of smooth muscle and elastic fibers

Bronchiole





Bronchiole

3.1.3 Terminal bronchiole

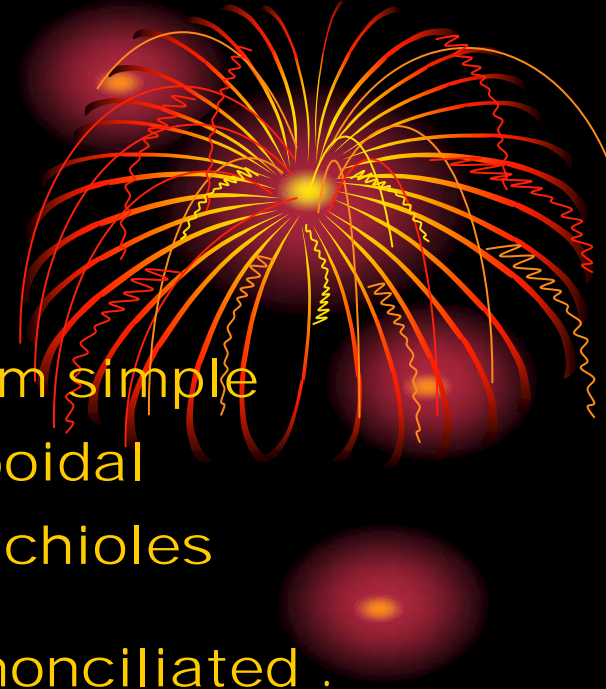
0.5mm in diameter

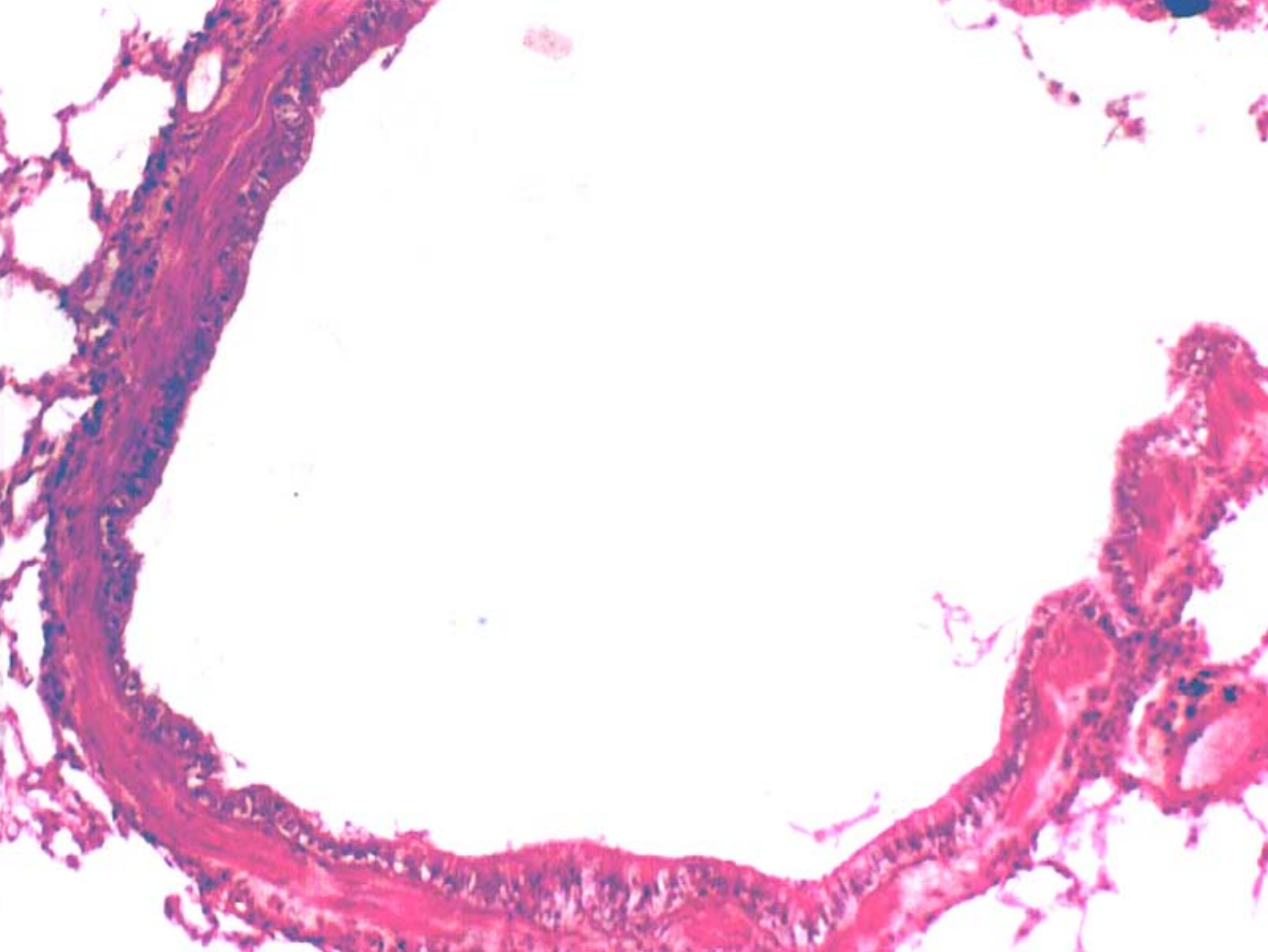
Terminal bronchiole lining layer ranges from simple columnar ciliated epithelium to simple cuboidal epithelium. the epithelium of terminal bronchioles contains only two cell types, ciliated and nonciliated .

with increasing of Clara cells

Goblet cells , tracheal glands , cartilage gradually disappear.

The smooth muscles increase comparatively to form a entire circular stratum in the deep layer of the mucous membrane



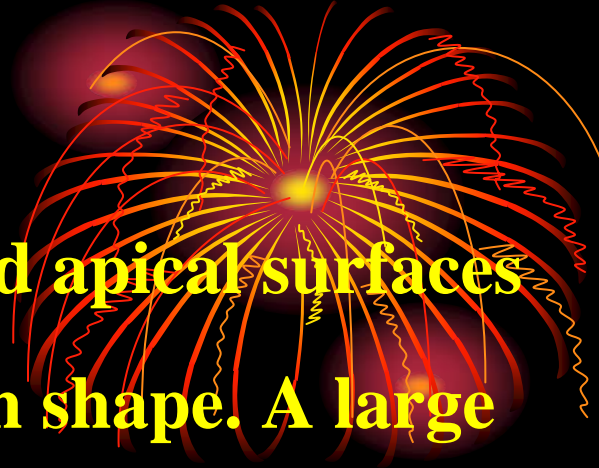

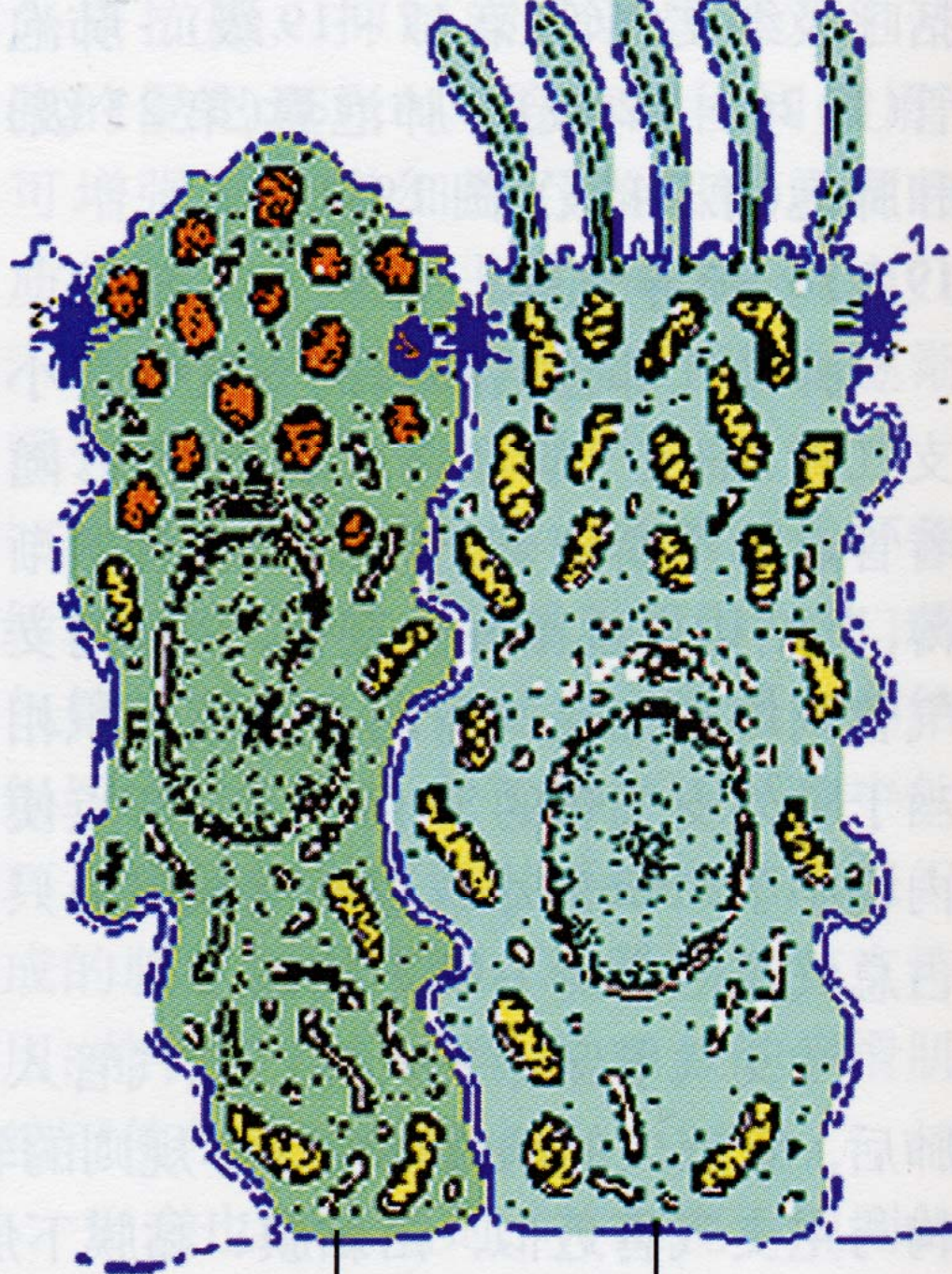
Clara cells

EM: columnar cells, whose dome-shaped apical surfaces project into the lumen, nuclei are oval in shape. A large quantity of rough endoplasmic reticulum and secretory granules are found in the cytoplasm.

function: producing proteolytic enzyme, oxidase system (biological oxidation and detoxification)


the cells retain a capacity to divide renewing the epithelium and differentiating into ciliated cells as well



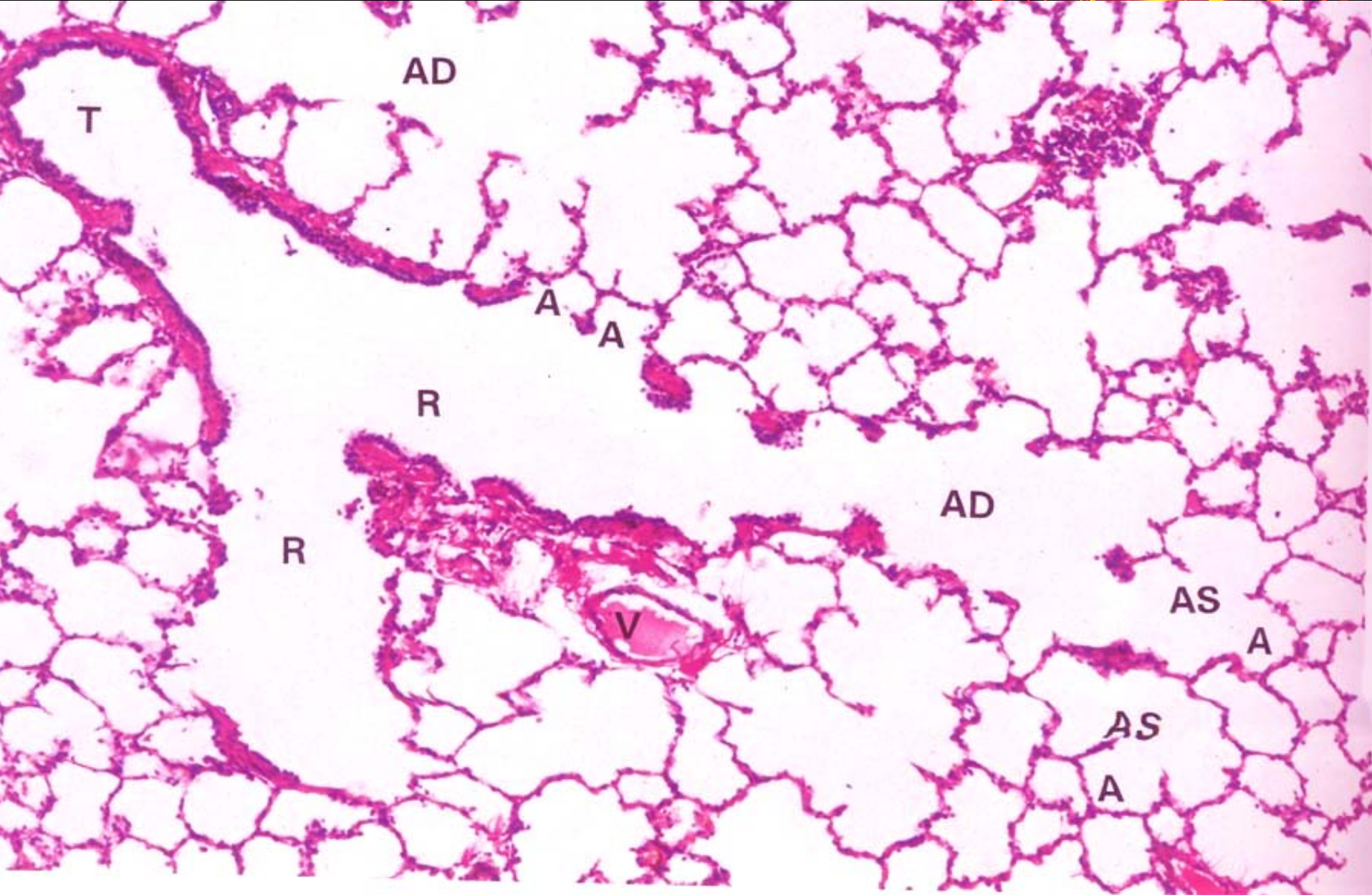



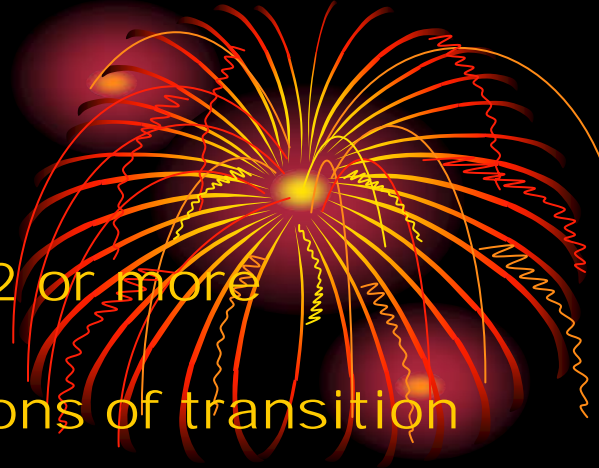
克拉拉细胞

纤毛细胞



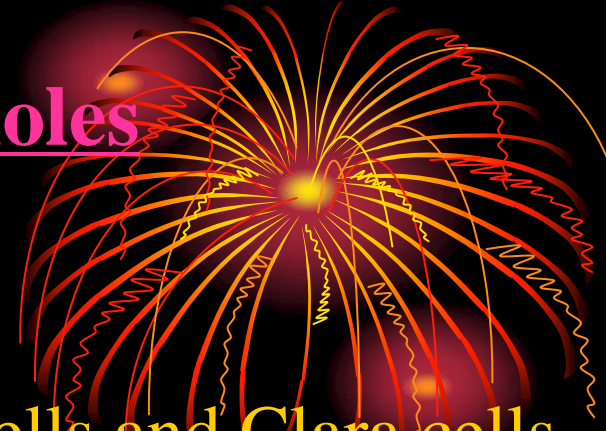3.2 Respiratory Portion





- Each terminal bronchiole subdivides into 2 or more respiratory bronchioles that serve as regions of transition between the conducting and respiratory portions of the respiratory system . The respiratory bronchiolar mucosa is structurally identical to that of the terminal bronchioles, except that their walls are interrupted by numerous saclike alveoli where gas exchange occurs.

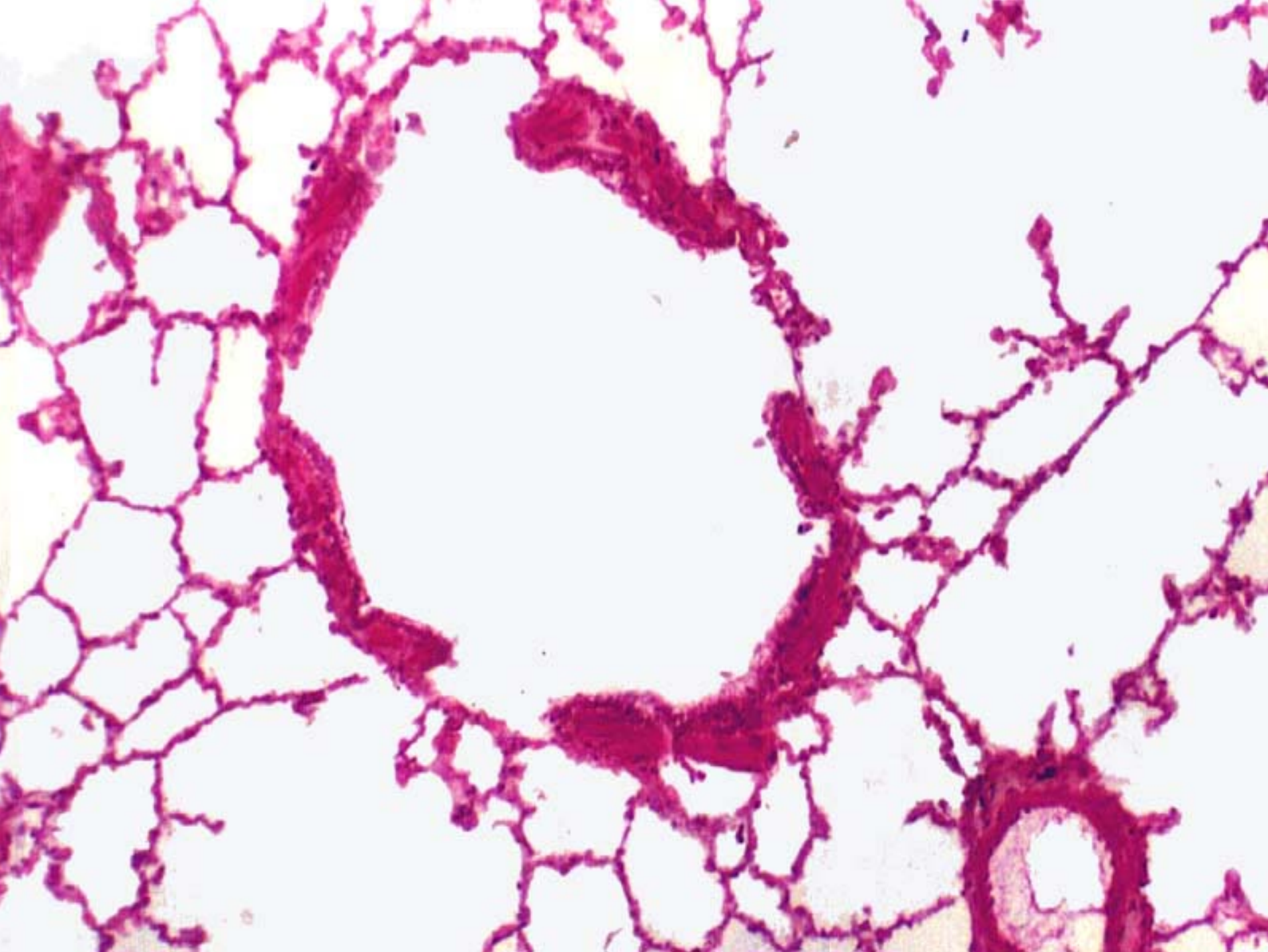
3.2.1 respiratory bronchioles



Simple cuboidal epithelium, with ciliated cells and Clara cells

With smooth muscles and elastic fibres

The walls of respiratory bronchioles are populated with alveoli

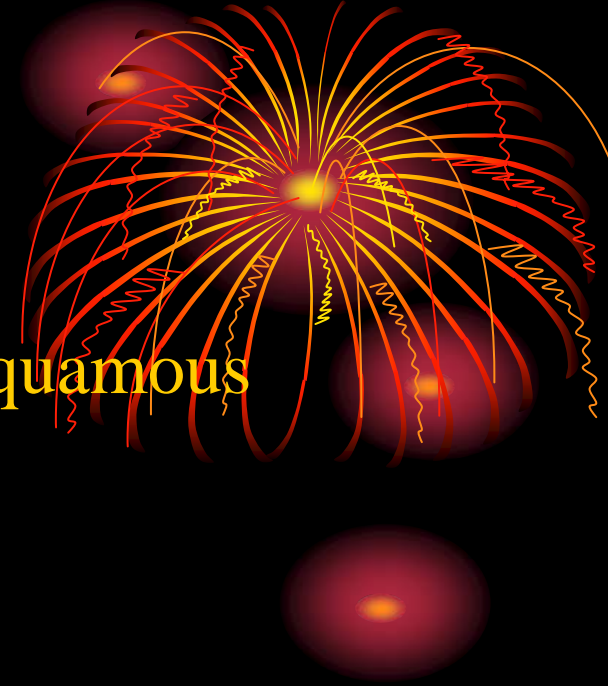

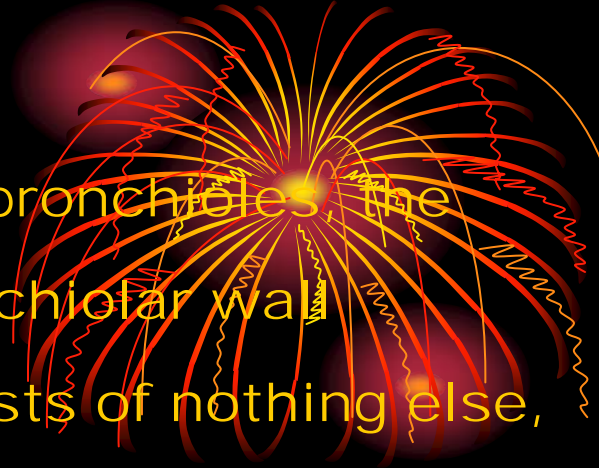3.2.2 alveolar ducts

Lined with simple cuboidal or attenuated squamous epithelial cells,

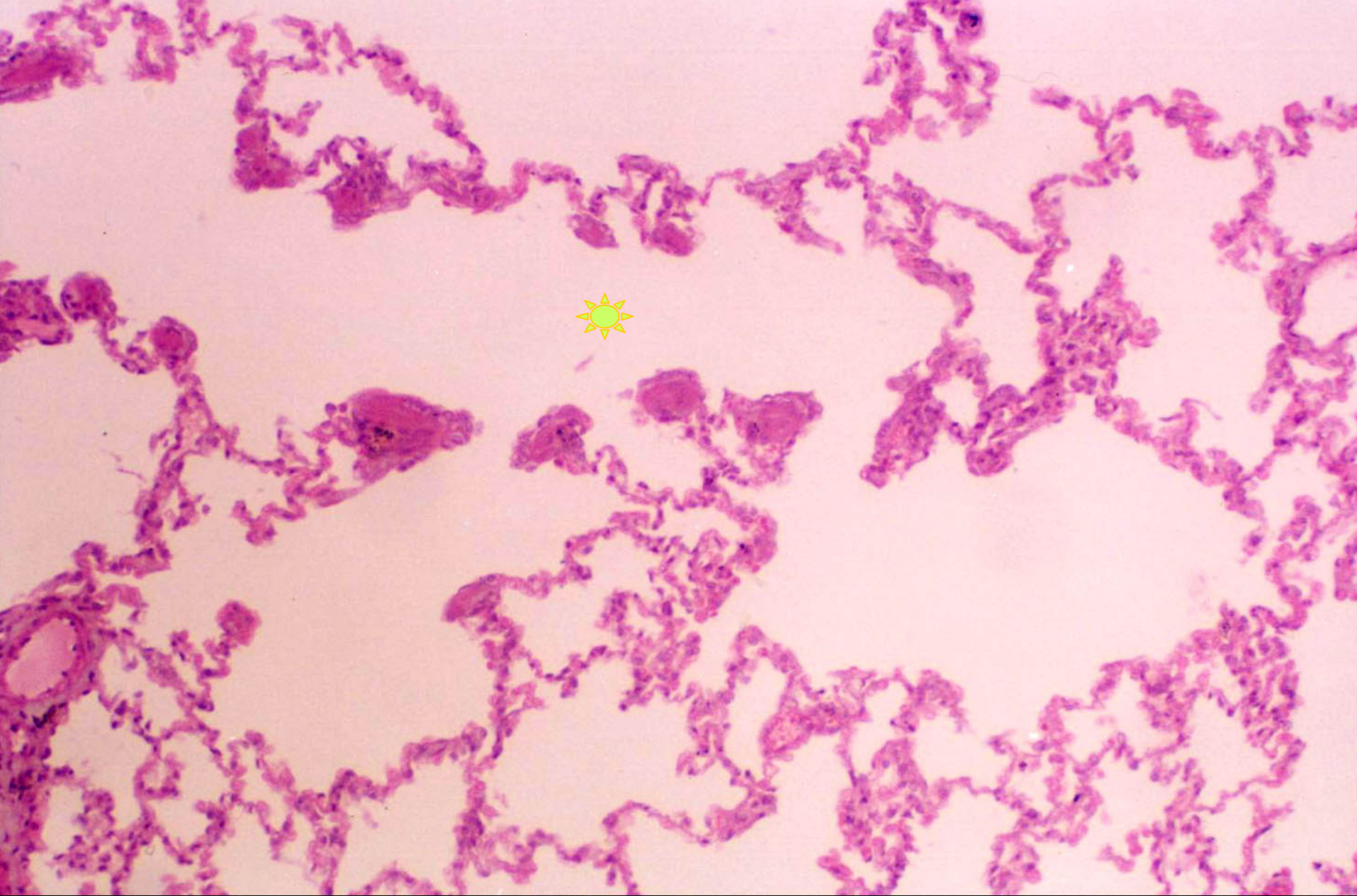
consisted of an interwoven network of smooth muscles

had knobs between adjacent alveoli





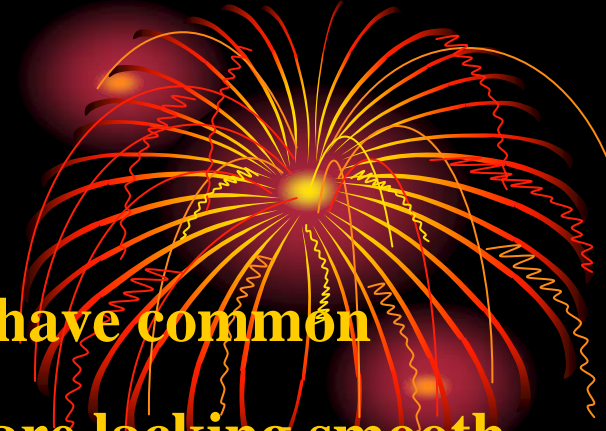- Proceeding distally along the respiratory bronchioles the number of alveolar openings into the bronchiolar wall becomes ever greater until the wall consists of nothing else, and the tube is now called an alveolar duct. the alveolar ducts are lined with extremely attenuated squamous alveolar cells. In the lamina propria surrounding the rim of the alveoli is a network of smooth muscle cells. These sphincter-like smooth muscle bundles appear as knobs between adjacent alveoli. Smooth muscle disappears at the distal ends of alveolar ducts. A rich matrix of elastic and collagen fibers provides the only support of the duct .

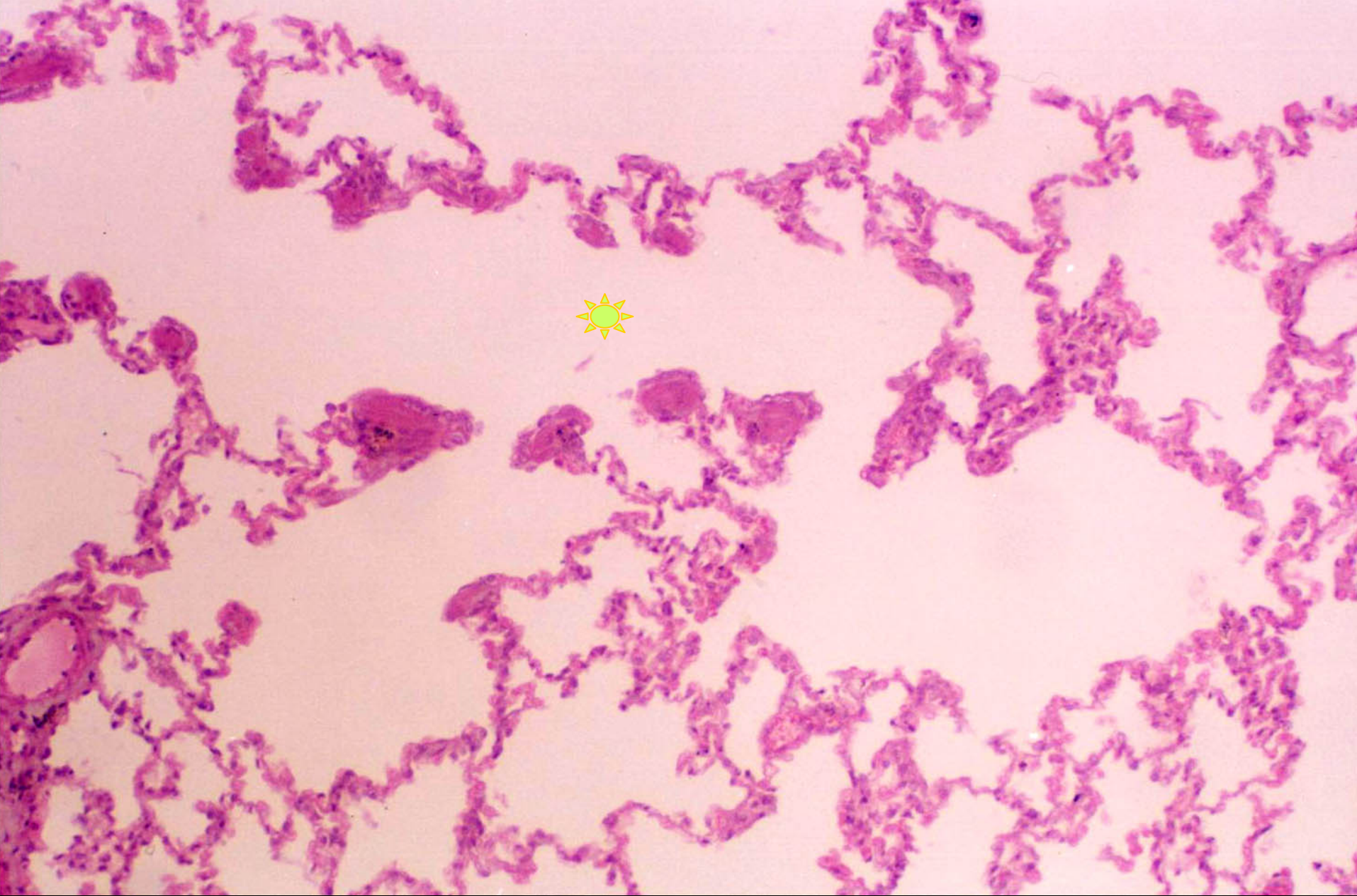


☀️肺泡管和肺泡囊光镜像

3.2.3 alveolar sacs

The alveolar sacs are clusters of alveoli that have common central spaces .The wall of the alveolar sacs are lacking smooth muscles . Elastic and reticular fibers form a complex network encircling the openings of atria, alveolar sacs, and alveoli. The elastic fibers enable the alveoli to expand with inspiration and to contract passively with expiration. The reticular fibers serve as a support that prevents overdistention.




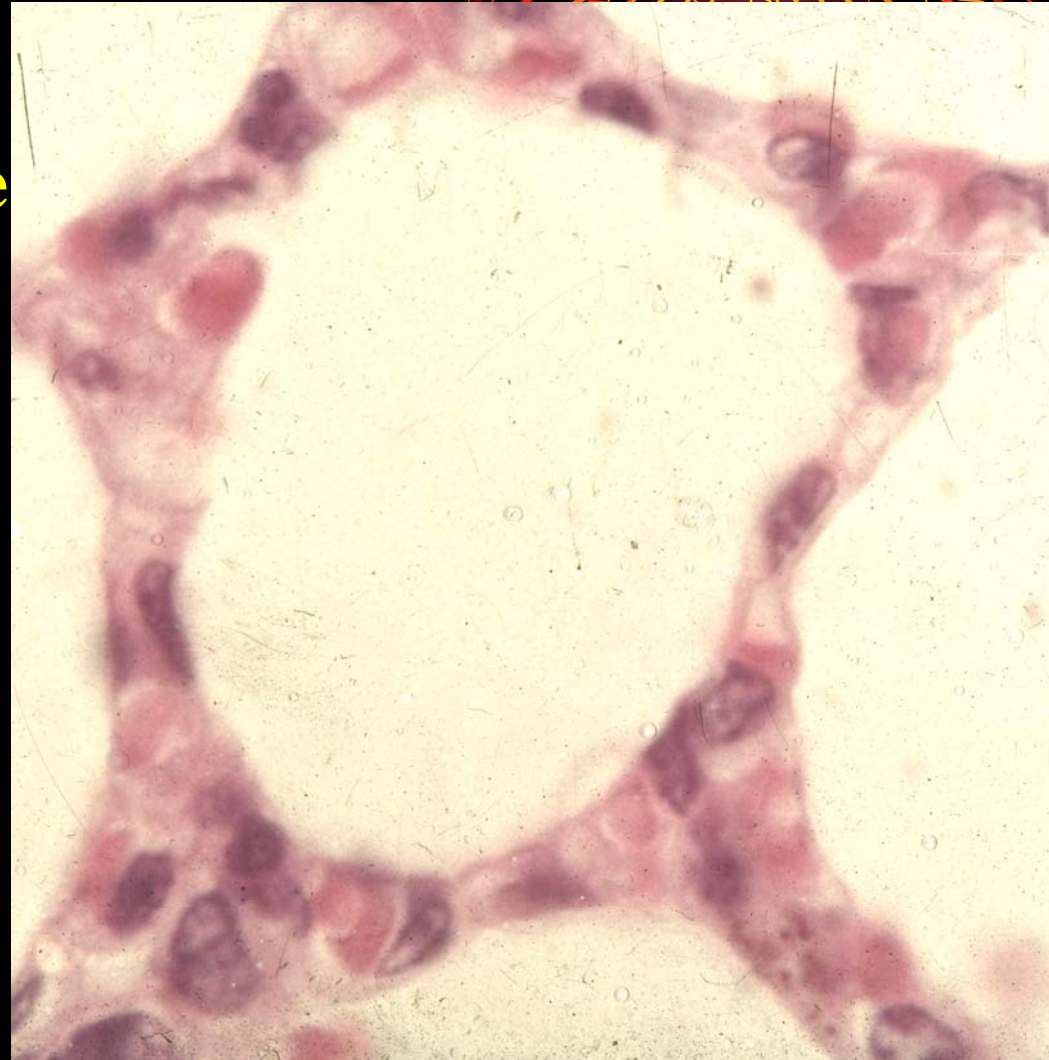


☀️肺泡管和肺泡囊光镜像

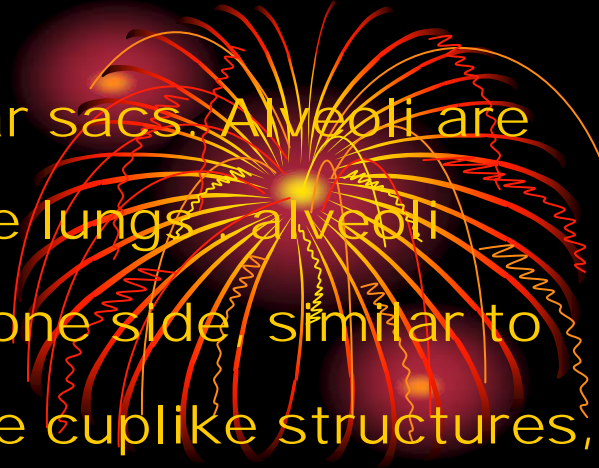
3.2.4 alveoli

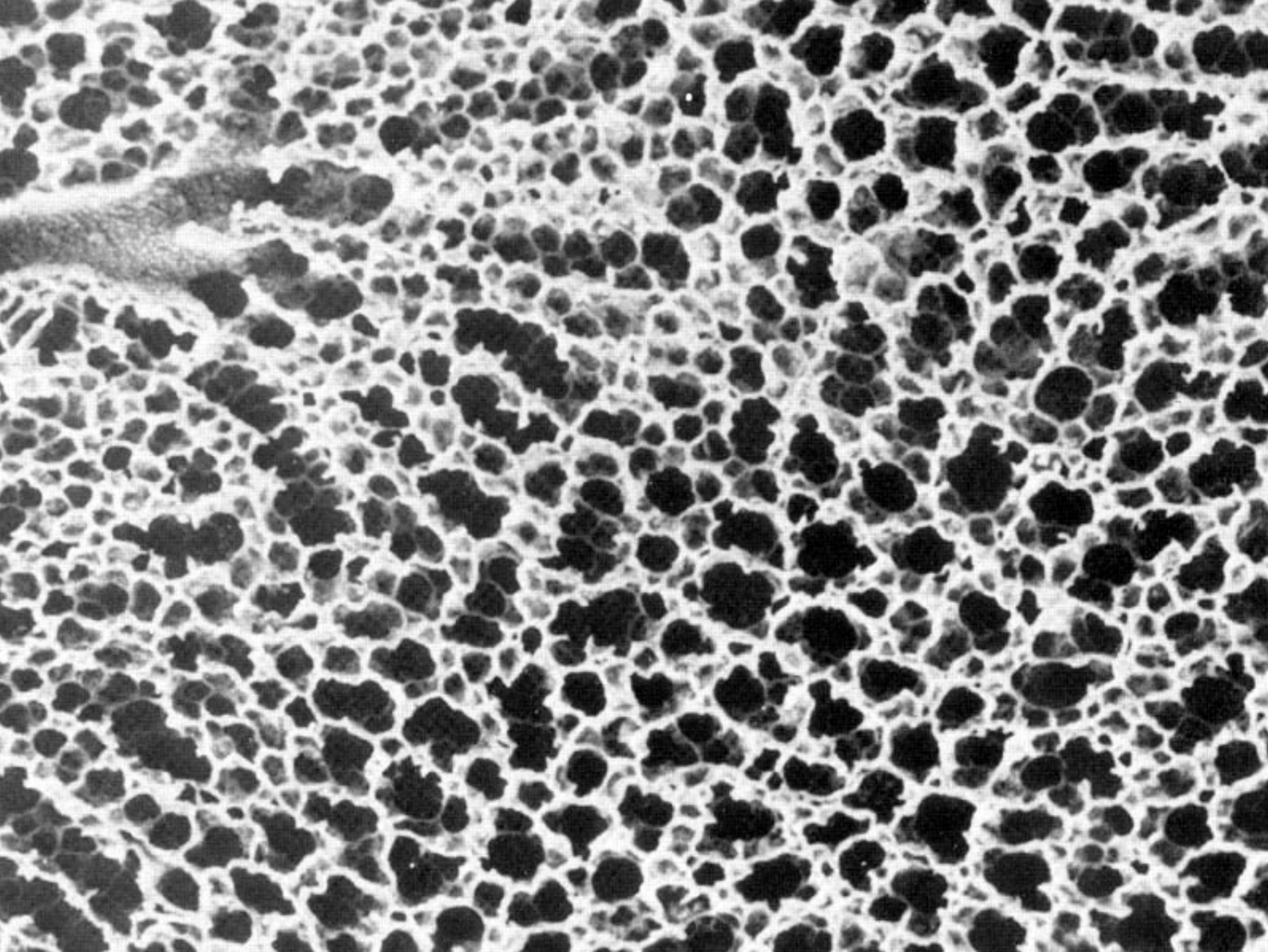
The wall of pulmonary alveoli consists of simple alveolar epithelium and basement membrane.

The connective tissue between adjacent the alveoli is termed the alveolar septum



- Alveoli are saclike evaginations of alveolar sacs. Alveoli are responsible for the spongy structure of the lungs. Alveoli resemble small pockets that are open on one side, similar to the honeycombs of a beehive. Within these cuplike structures, O_2 and CO_2 are exchanged between the air and the blood. The structure of the alveolar walls is specialized for enhancing diffusion between the external and internal environments. Generally, each wall lies between 2 neighboring alveoli is called an interalveolar septum, or wall. An interalveolar septum consists of 2 thin squamous epithelial layers between which lie capillaries, elastic and reticular fibers, and connective tissue matrix and cells.





(1) the alveolar epithelium

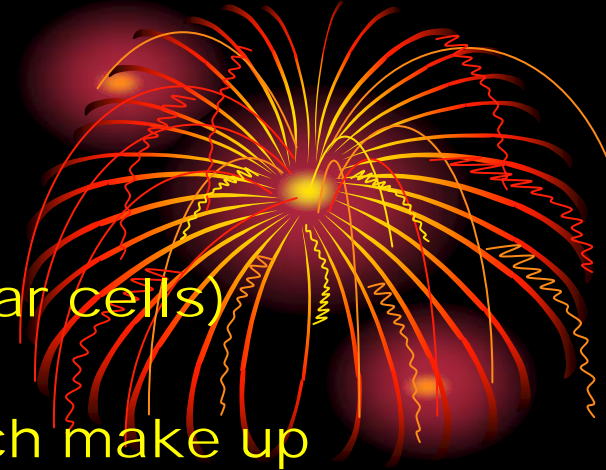
1) Type I alveolar cells (squamous alveolar cells)

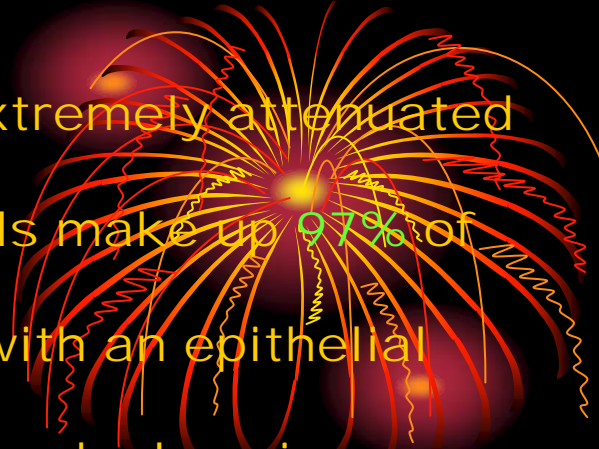LM: a thin squamous epithelium, which make up

97% of the alveolar surfaces.

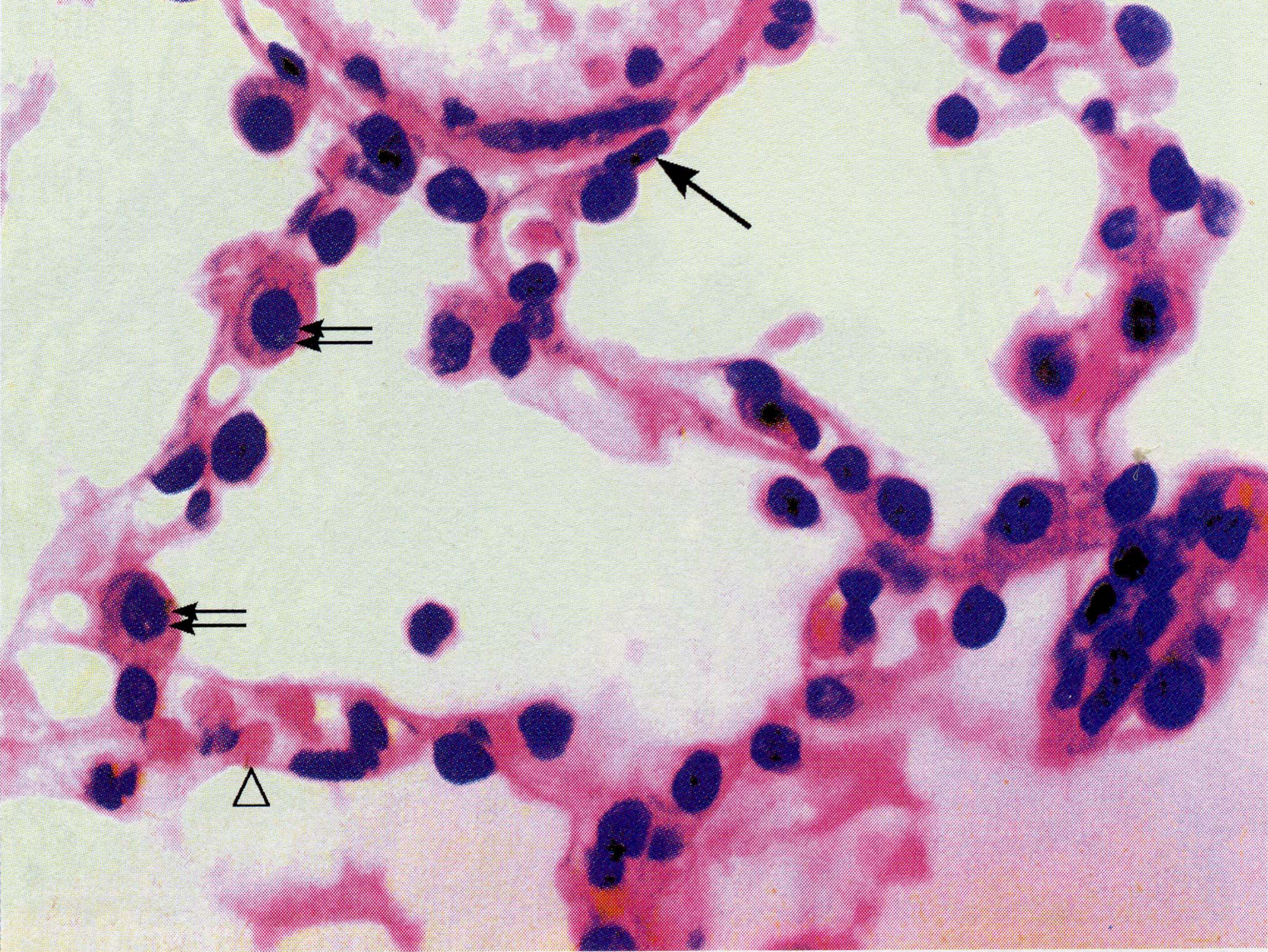
EM: tight junctions, pinocytotic vesicles (turnover of surfactant, the removal of small particulate contaminants from the outer surface)

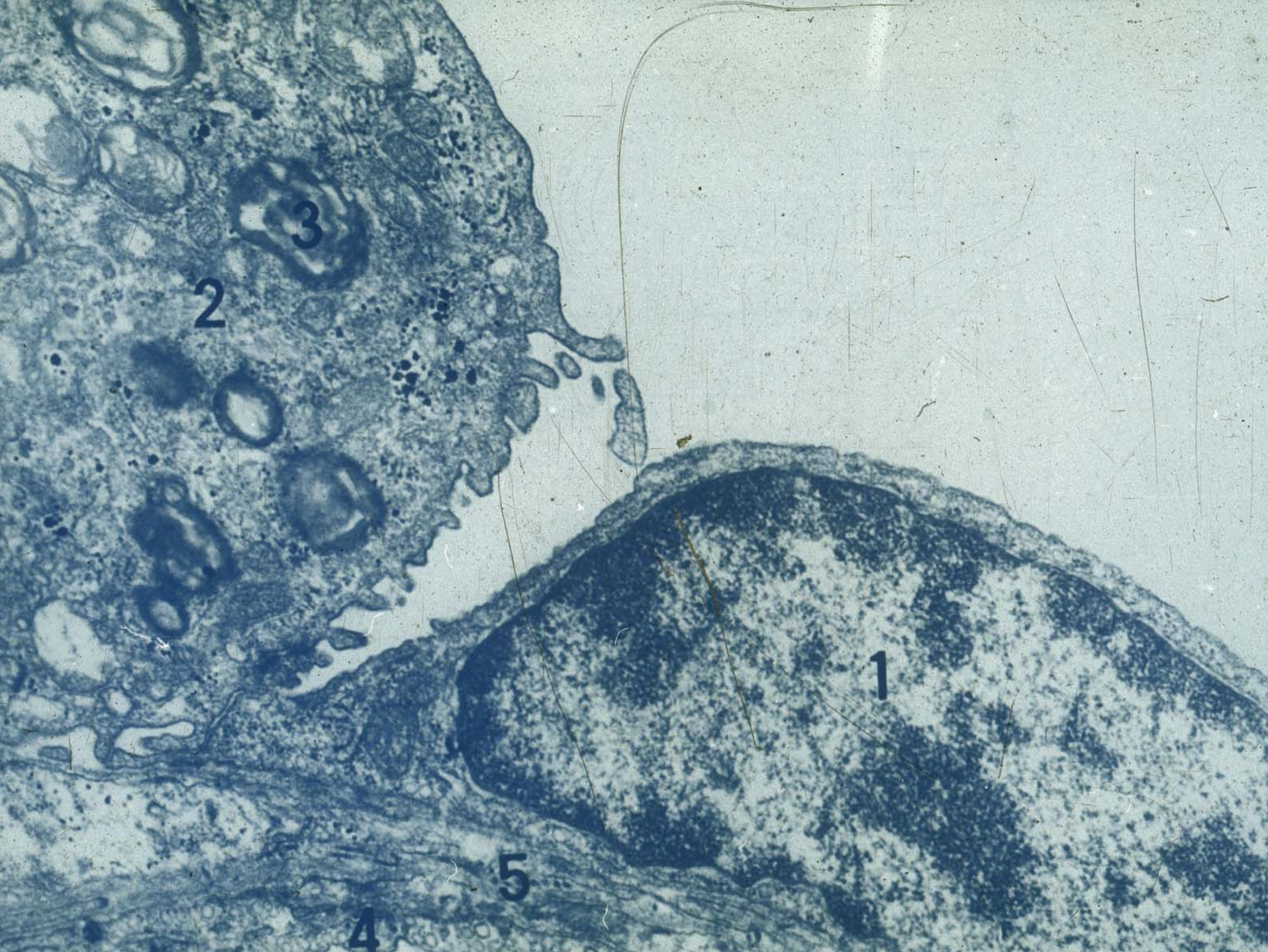
function: provide a barrier of minimal thickness that is readily permeable to gases.






- **Type I cells**, or squamous alveolar cells, are extremely attenuated cells that line the alveolar surfaces. Type I cells make up 97% of the alveolar surfaces . all alveoli are covered with an epithelial lining . Organelles such as the Golgi complex, endoplasmic reticulum, and mitochondria are grouped around the nucleus, **reducing the thickness** of the blood-air barrier and leaving large areas of cytoplasm virtually free of organelles. The cytoplasm in the thin portion contains abundant pinocytotic vesicles, which may play a role in the turnover of surfactant and the removal of small particulate contaminants from the outer surface. In addition to desmosomes, all type I epithelial cells have occluding junctions that prevent the leakage of tissue fluid into the alveolar air space.





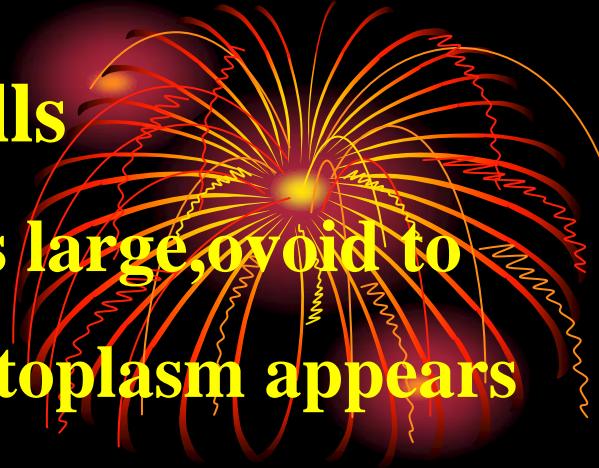

Cryofracture preparation showing an occluding junction between 2 type I epithelial cells of the alveolar lining.

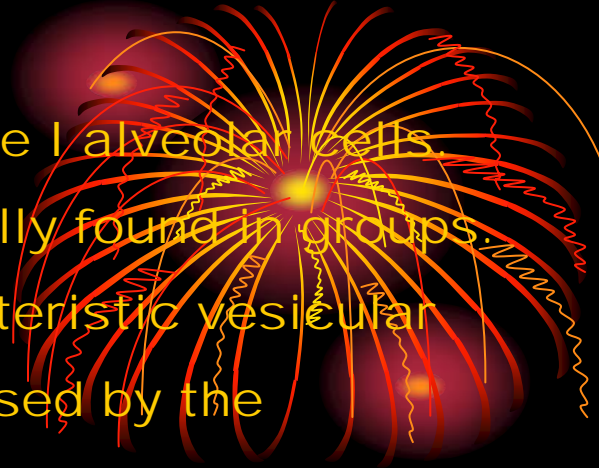2) type II alveolar cells

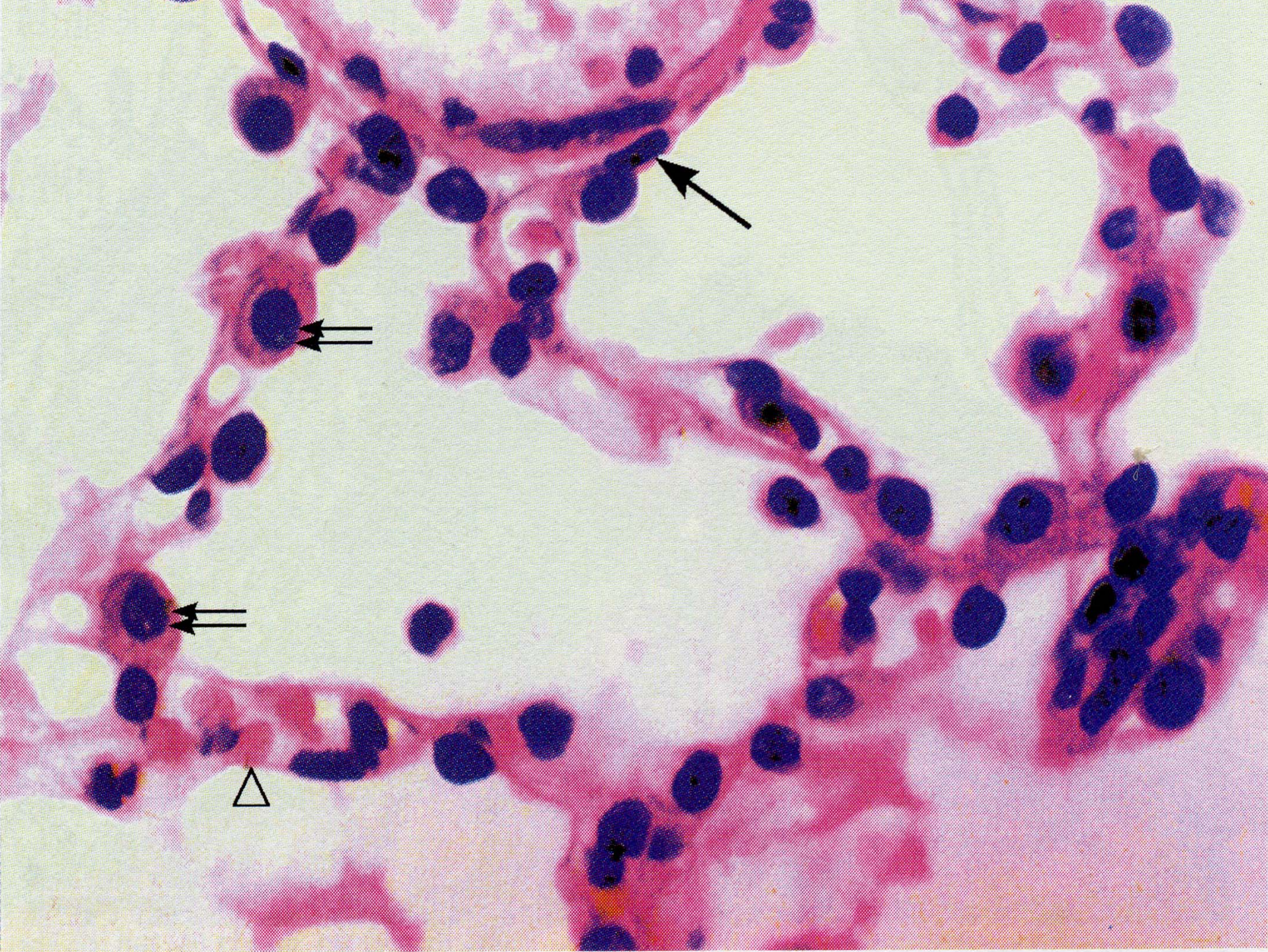
LM: cuboidal-shaped cells, the nucleus is large, ovoid to round, and light-staining, and the cytoplasm appears vacuolated or foamy.

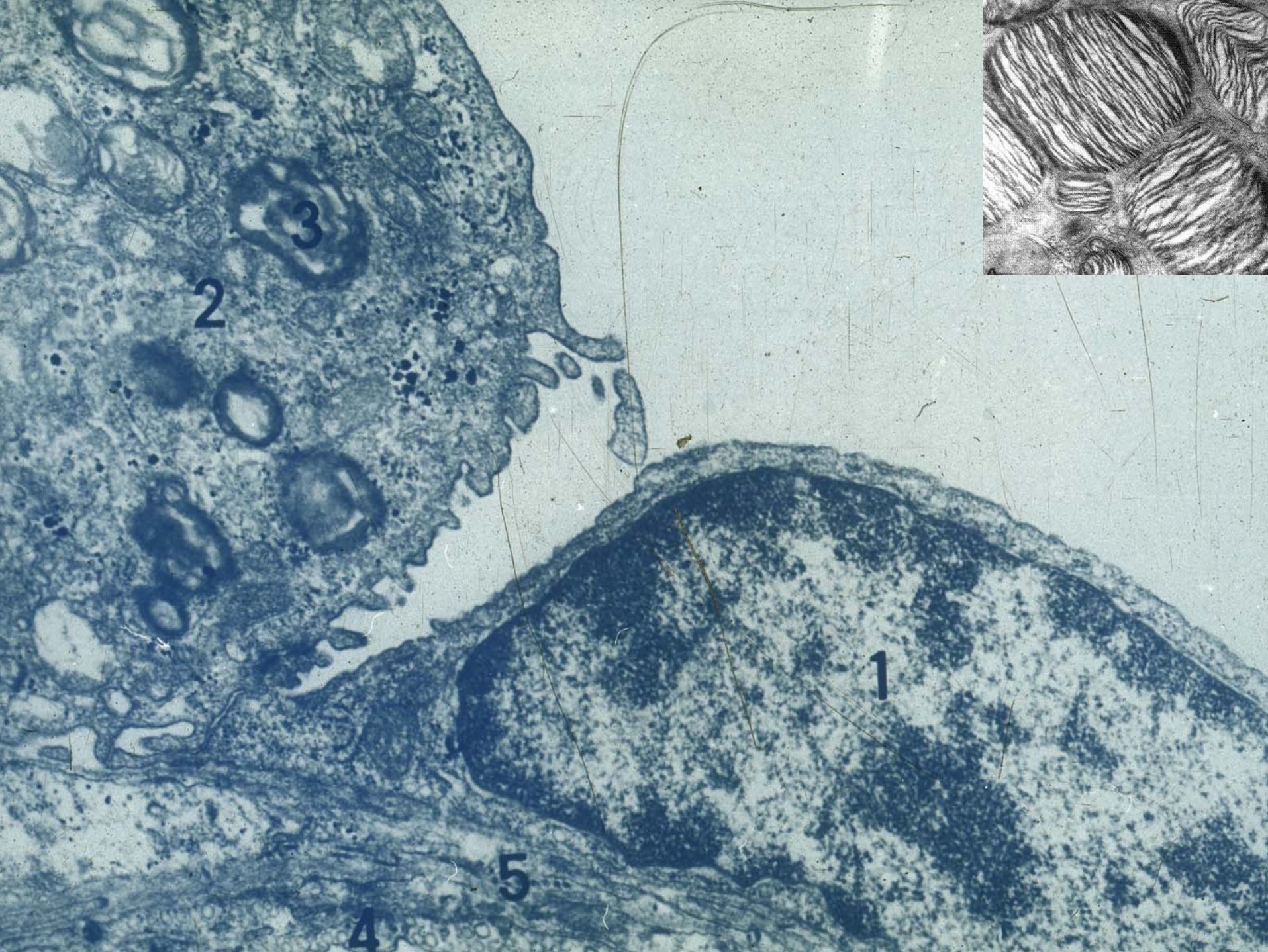
EM: microvilli, RER, Golgi complex, Lamellar bodies, which average 1-2 micrometers in diameter, contain concentric or parallel lamellae limited by a unit membrane .which contains phospholipid, glycosaminoglycans and protein
function: secreting surfactant, that lowers alveolar surface tension



- Type II cells are interspersed among the type I alveolar cells. Type II cells are rounded cells that are usually found in groups. In histologic sections, they exhibit a characteristic vesicular or foamy cytoplasm. These vesicles are caused by the presence of lamellar bodies that are preserved and evident in tissue prepared for electron microscopy. Lamellar bodies, contain concentric or parallel lamellae limited by a unit membrane. these bodies, which contain phospholipids, glycosaminoglycans, and proteins, are continuously synthesized and released at the apical surface of the cells. The lamellar bodies give rise to a material that spreads over the alveolar surfaces, providing an extracellular alveolar coating, pulmonary surfactant

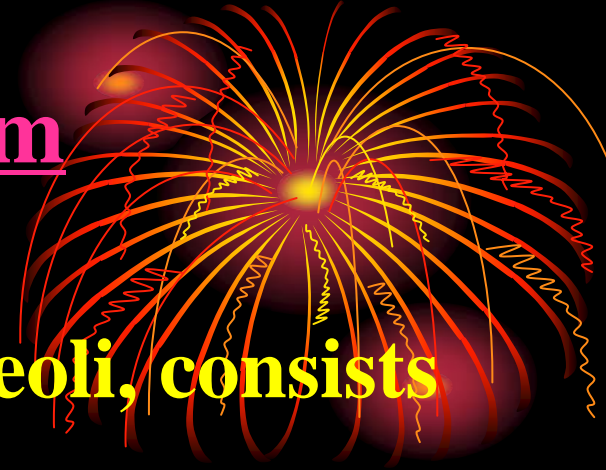


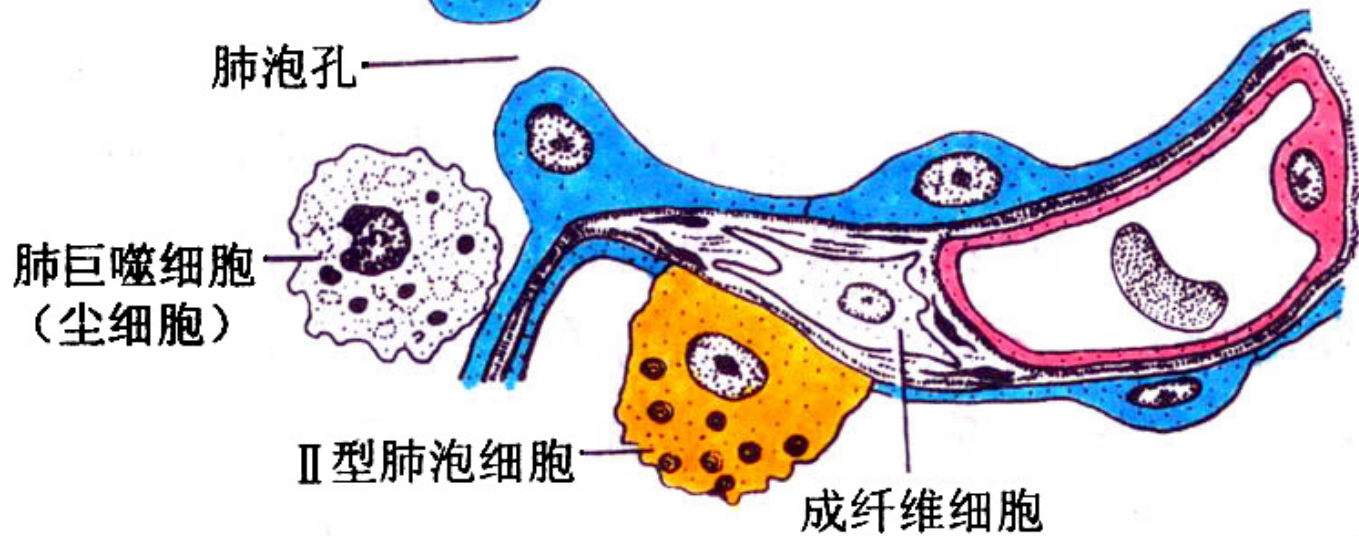
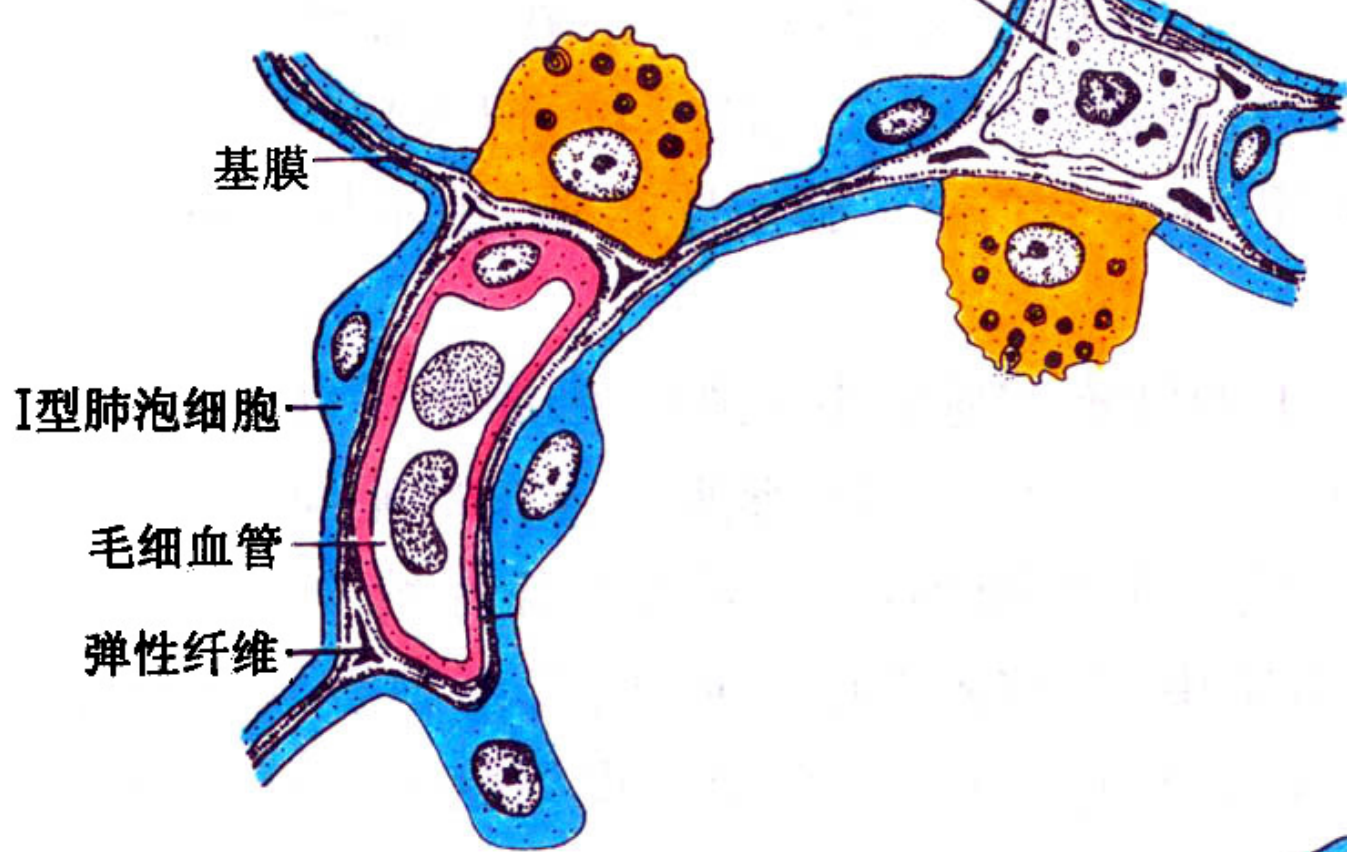


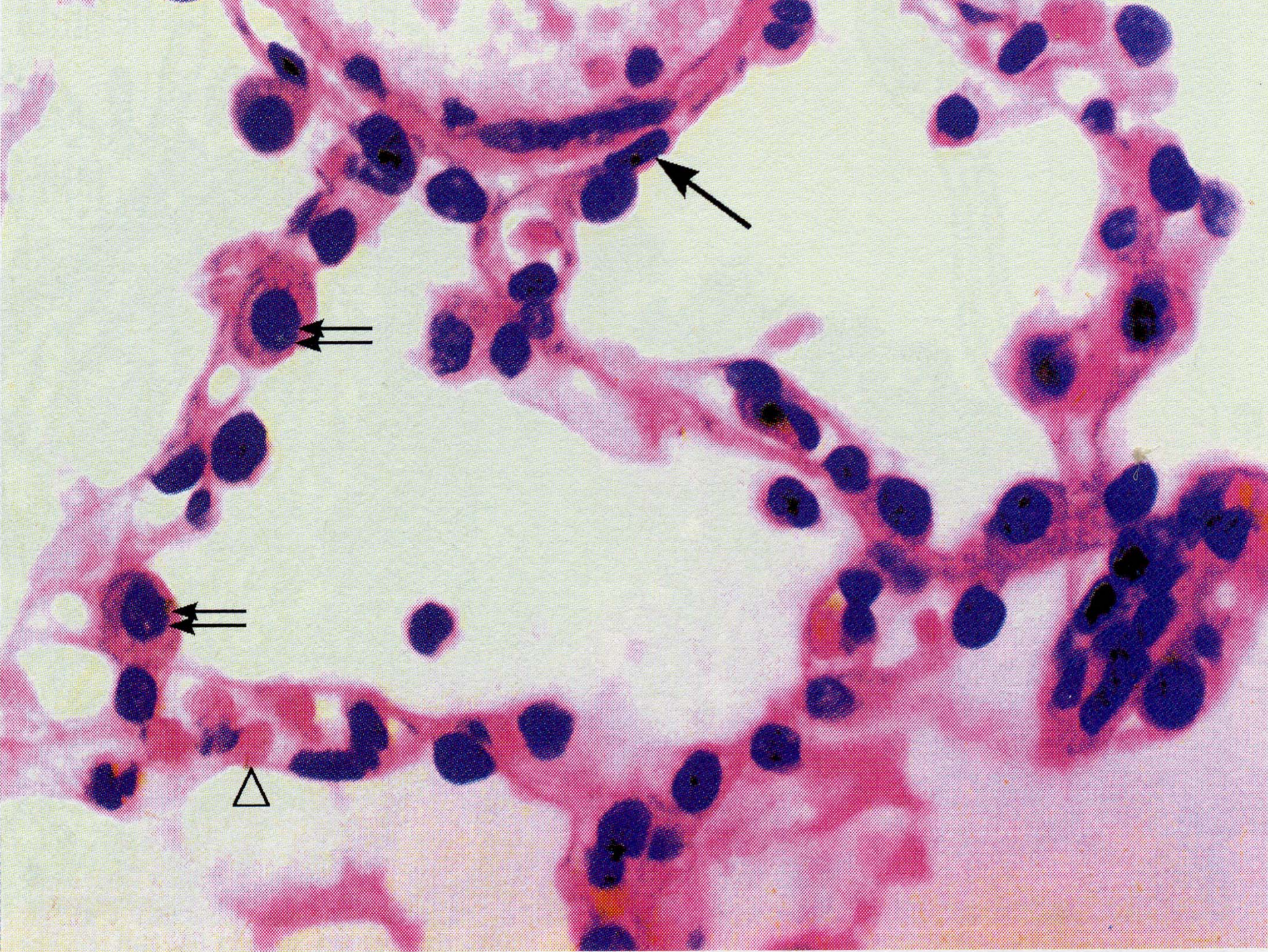


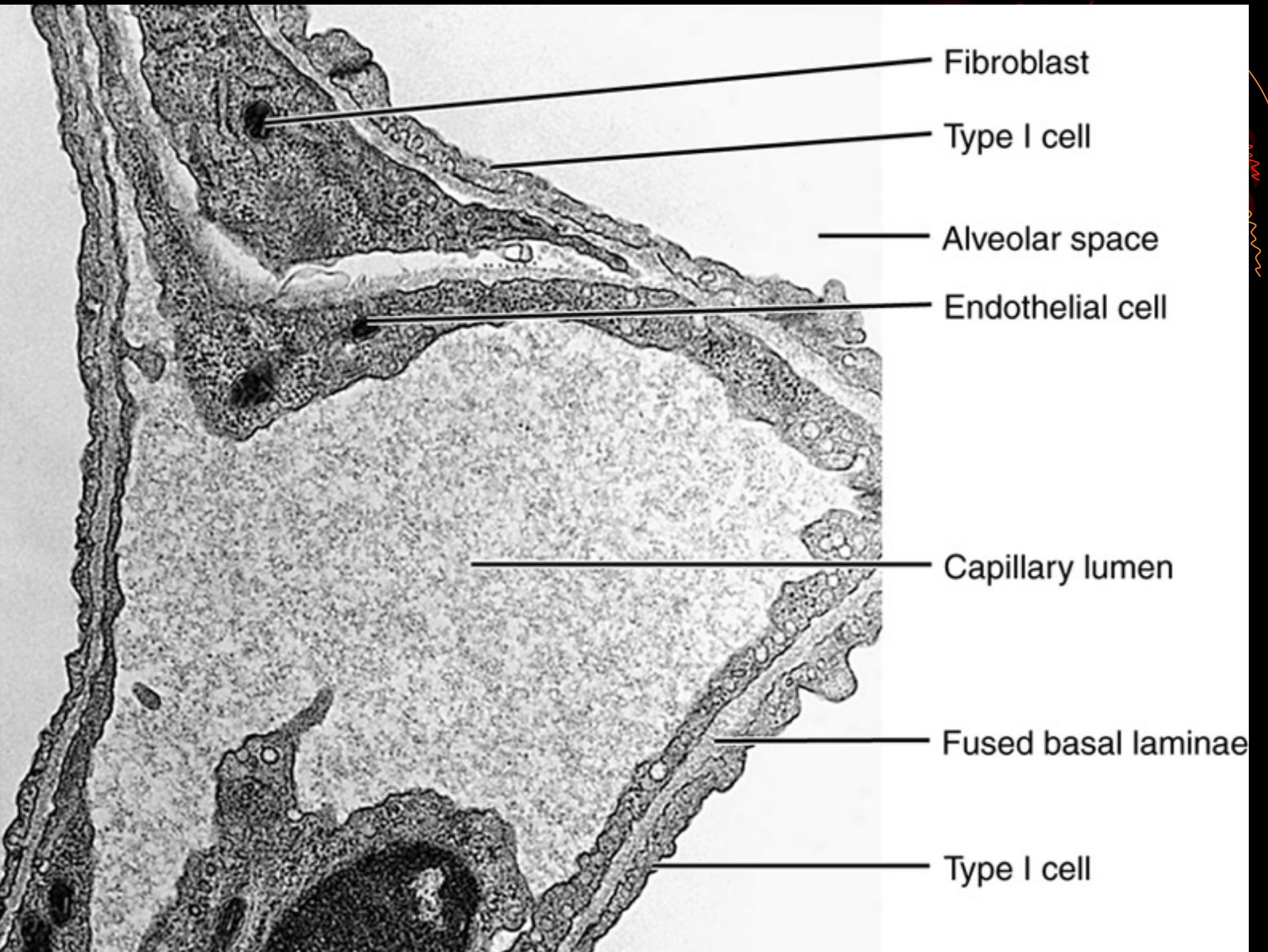
(2) alveolar septum

**lie between 2 neighboring alveoli, consists
of thin connective tissue, continuous
capillaries meshwork, elastic fibers and
reticular fibers, macrophages, plasma
cells and mast cells**









Fibroblast

Type I cell


Alveolar space

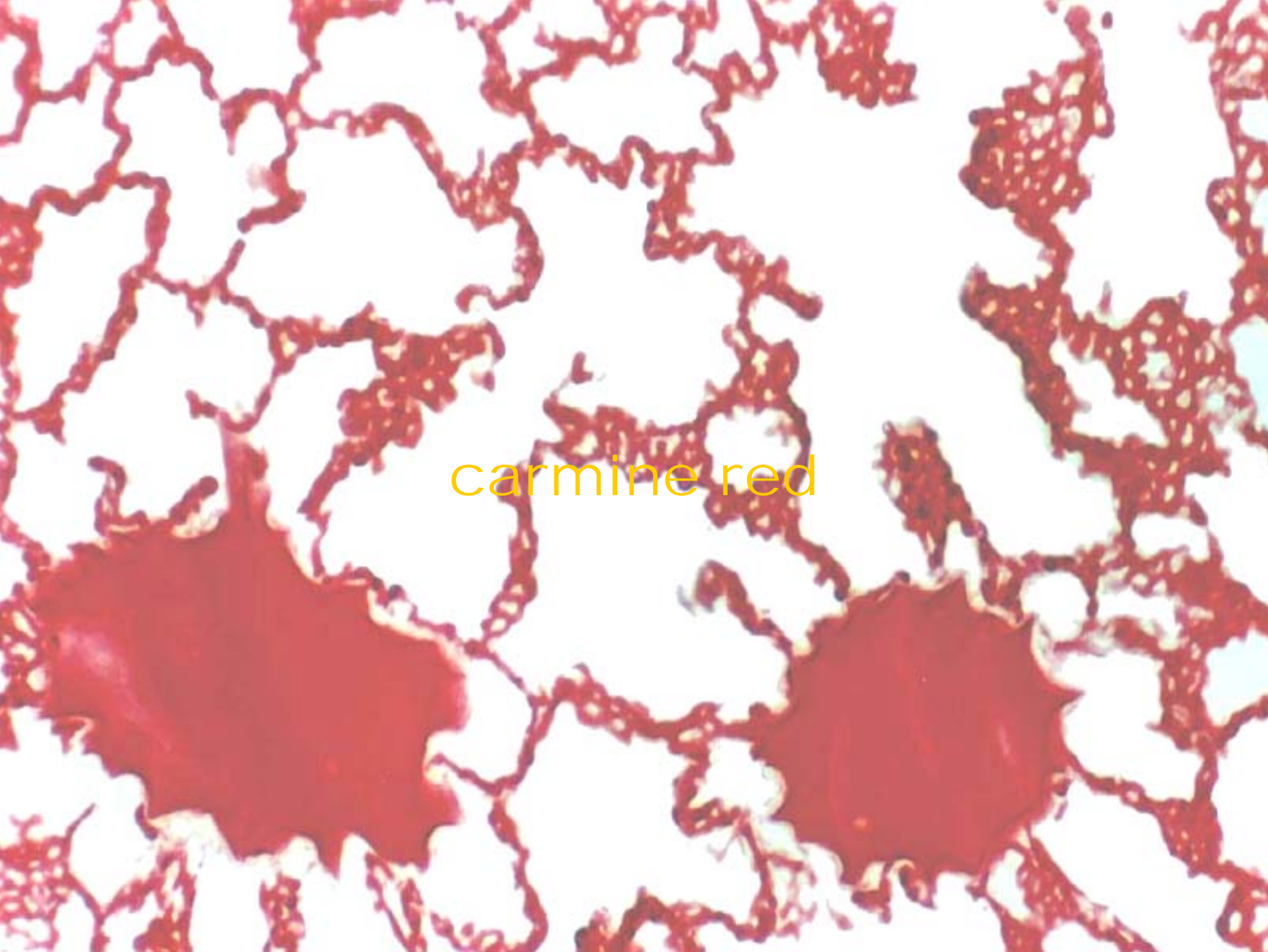
Endothelial cell

Capillary lumen

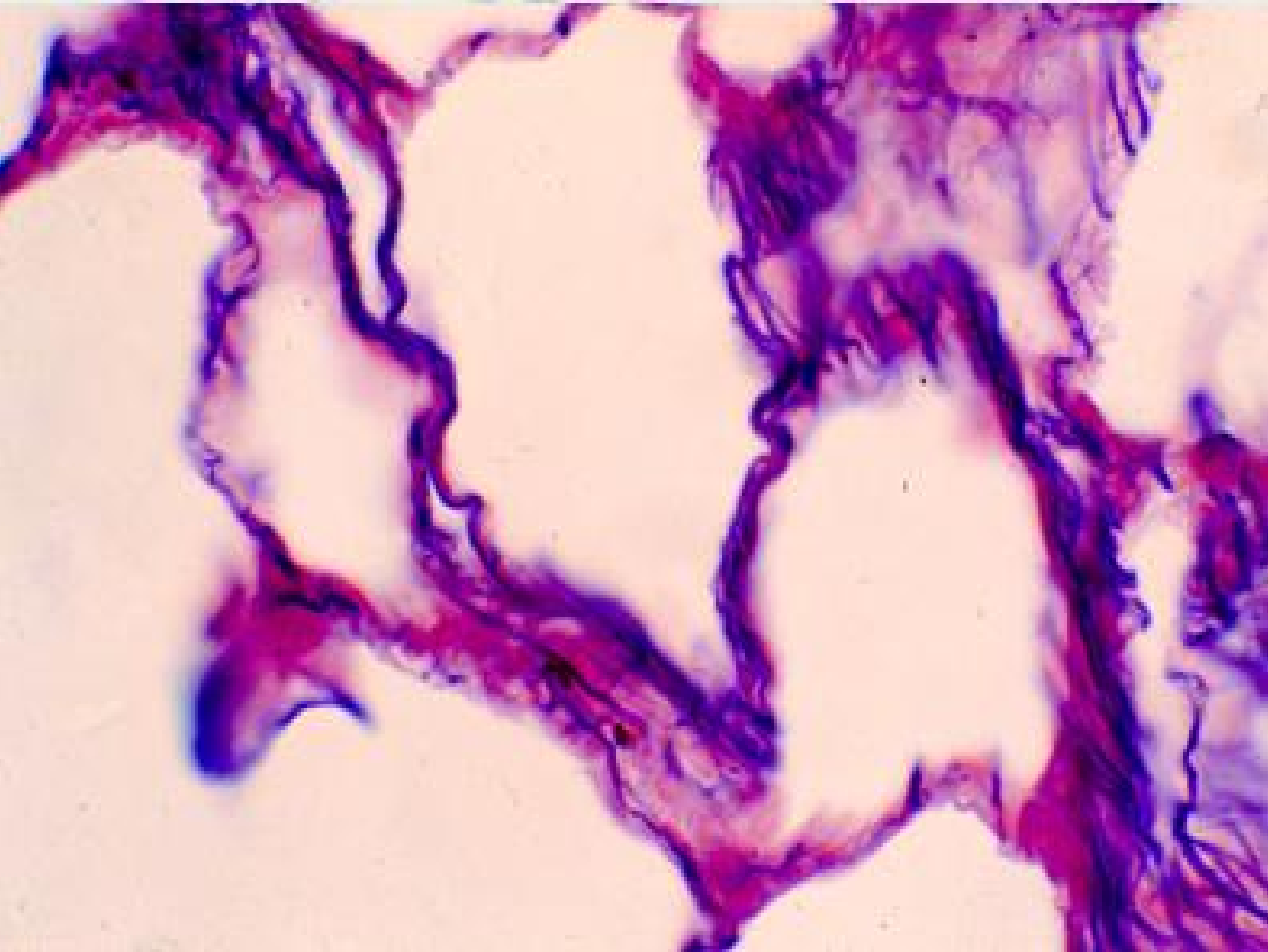
Fused basal laminae

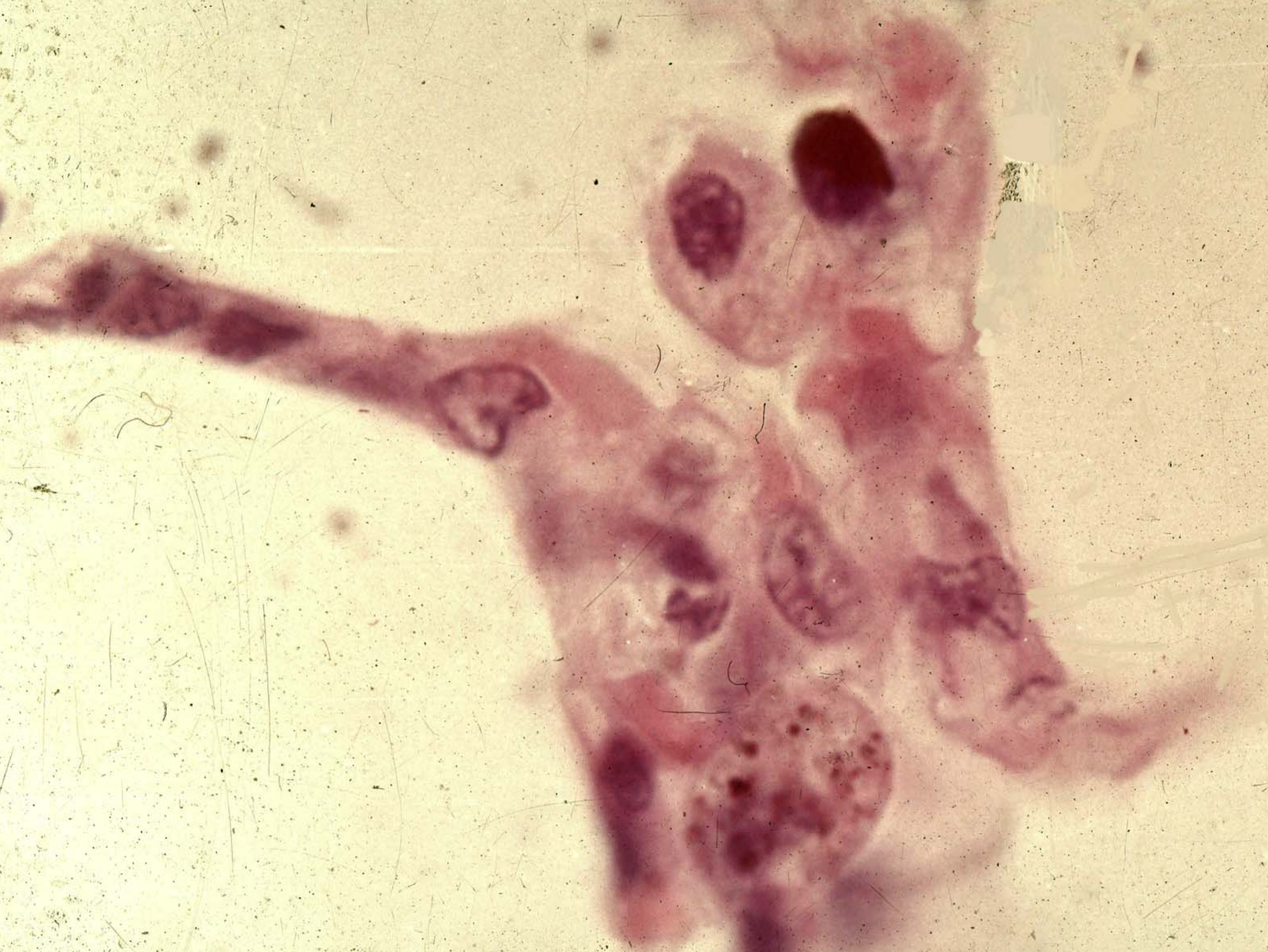Type I cell

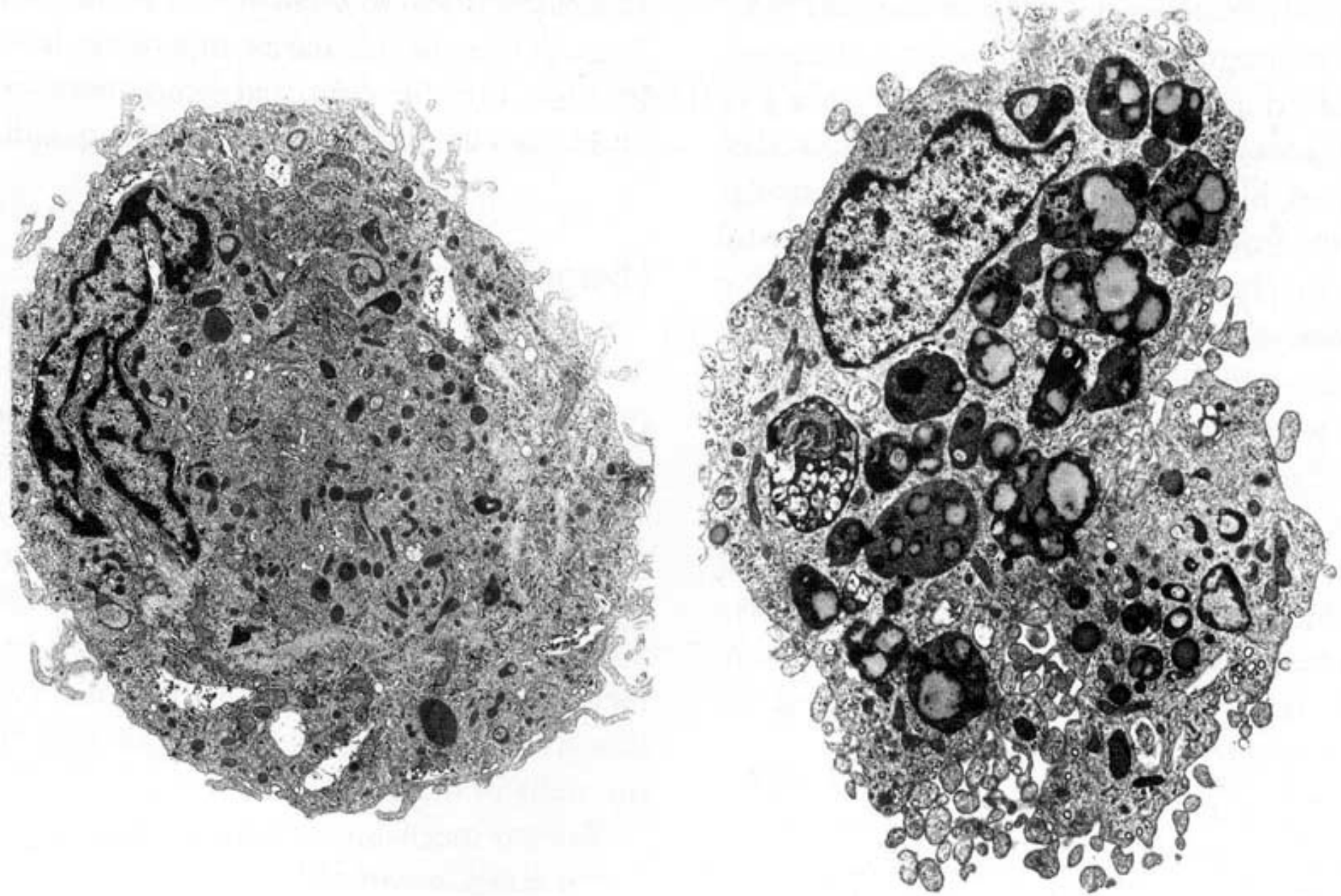




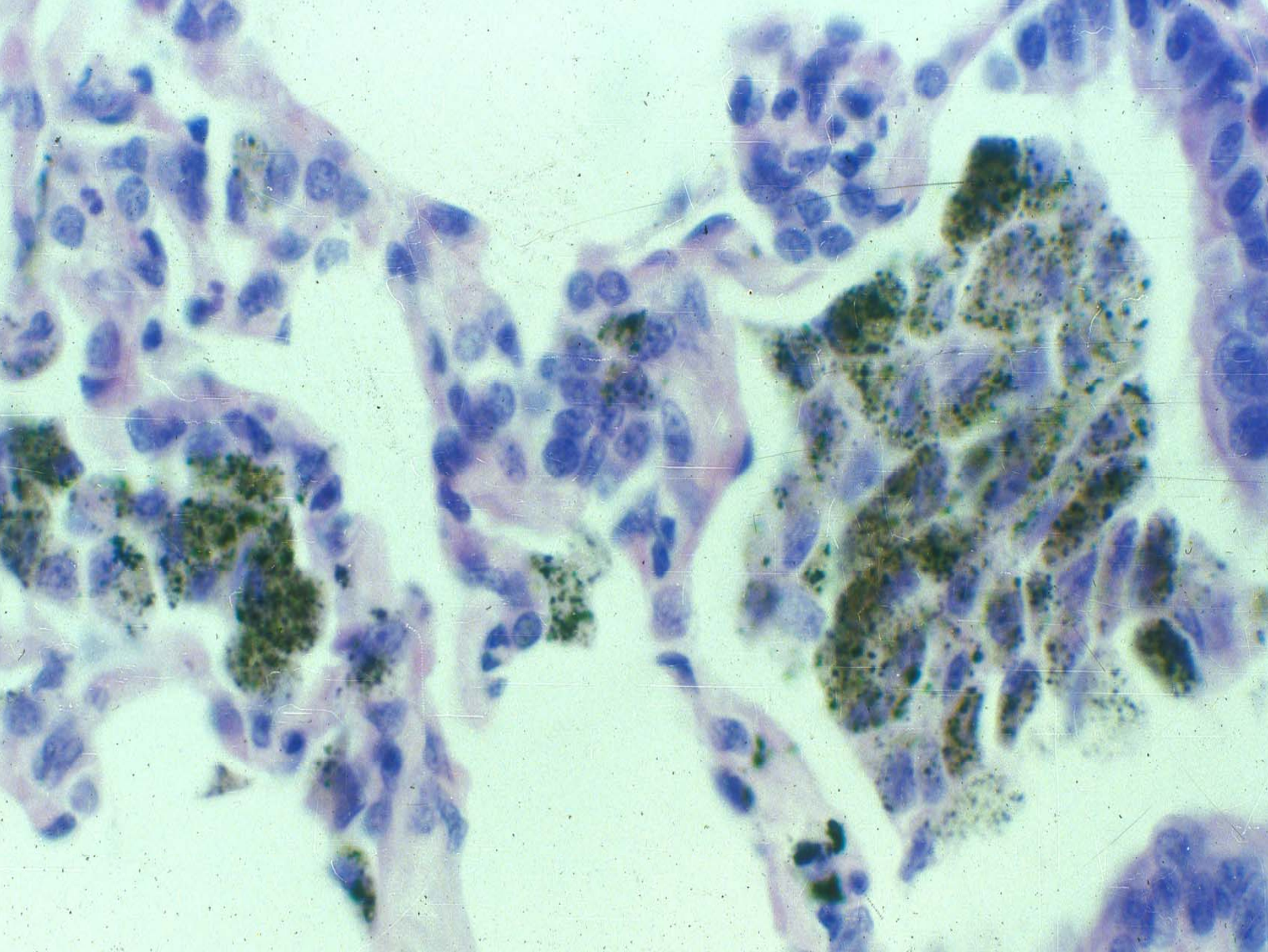
carmine red








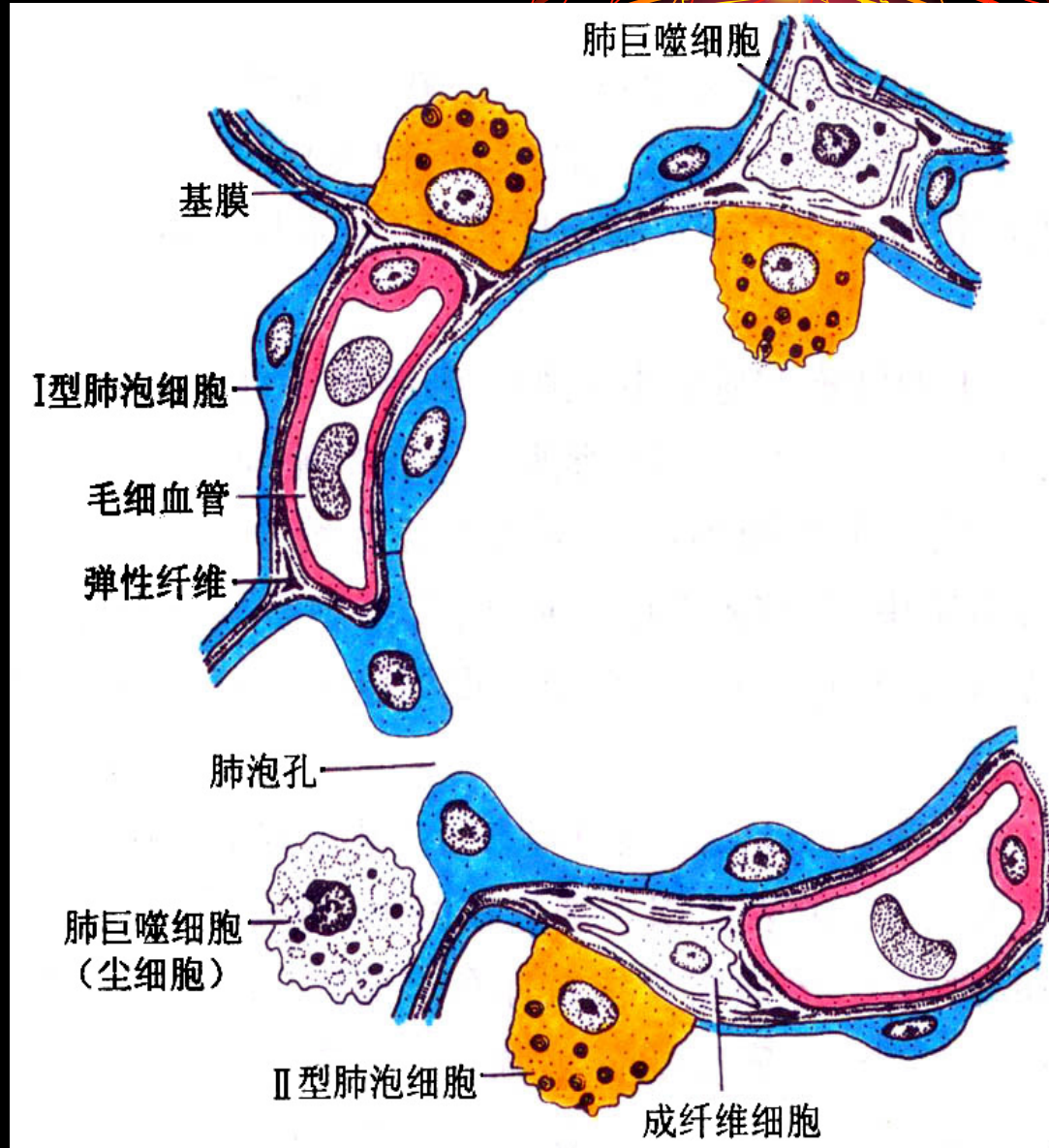
肺巨噬细胞电镜像（左:nonsmokers 右:smokers）




(3) alveolar pore



Alveolar pores connect neighboring alveoli
these pores equalize air pressure in the alveoli





2

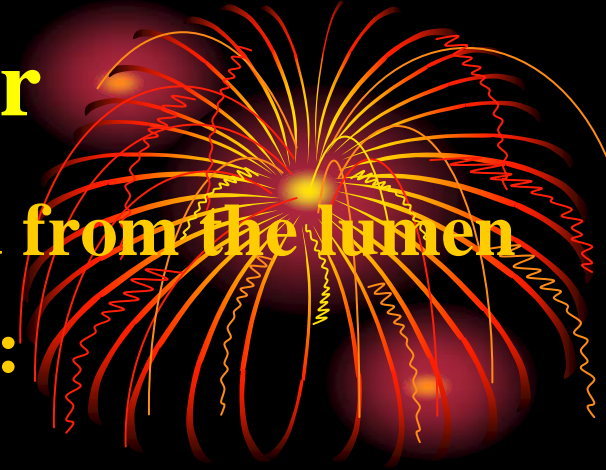1

(4) blood-air barrier

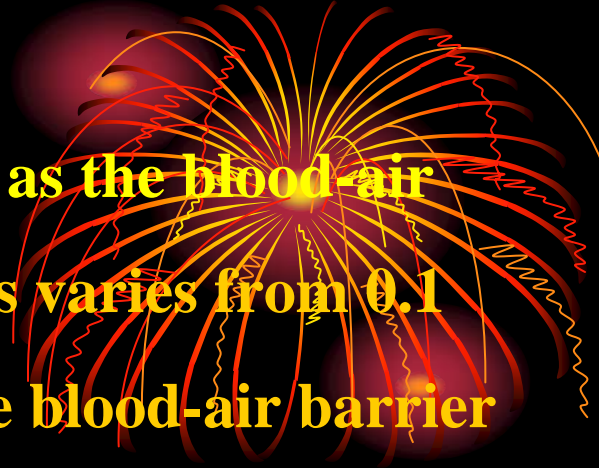The lumen of the alveolus is separated from the lumen of the blood capillary by the following:





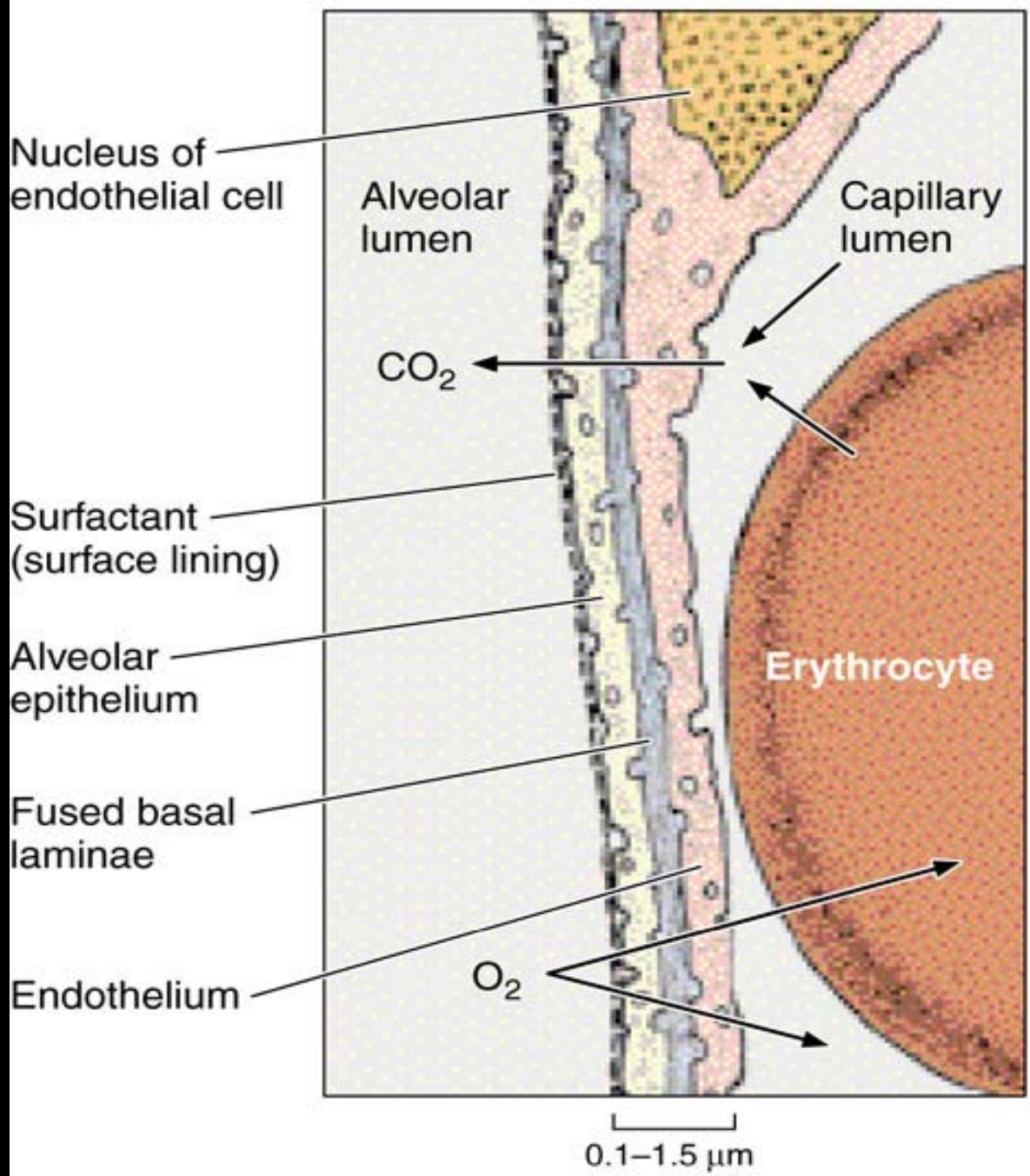
- 1) surfactant**
- 2) The alveolar squamous epithelium or type I cells**
- 3) The epithelial basement membrane**
- 4) A minute tissue space**
- 5) The blood capillary basement membrane**
- 6) The capillary squamous endothelium**

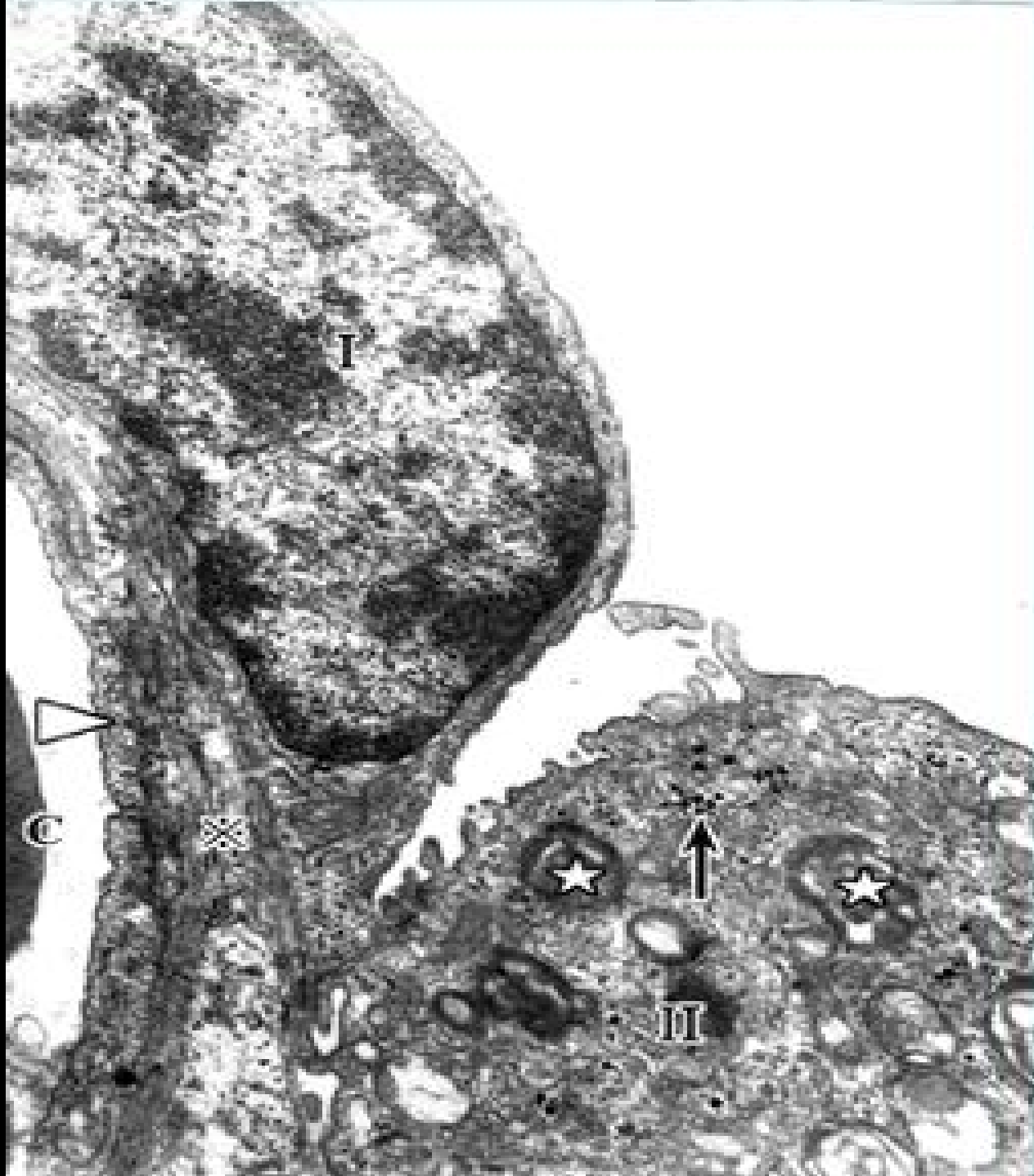
function: It is at the blood-air barrier that gaseous exchange takes place between the air in the alveolar lumen and the blood within the capillary



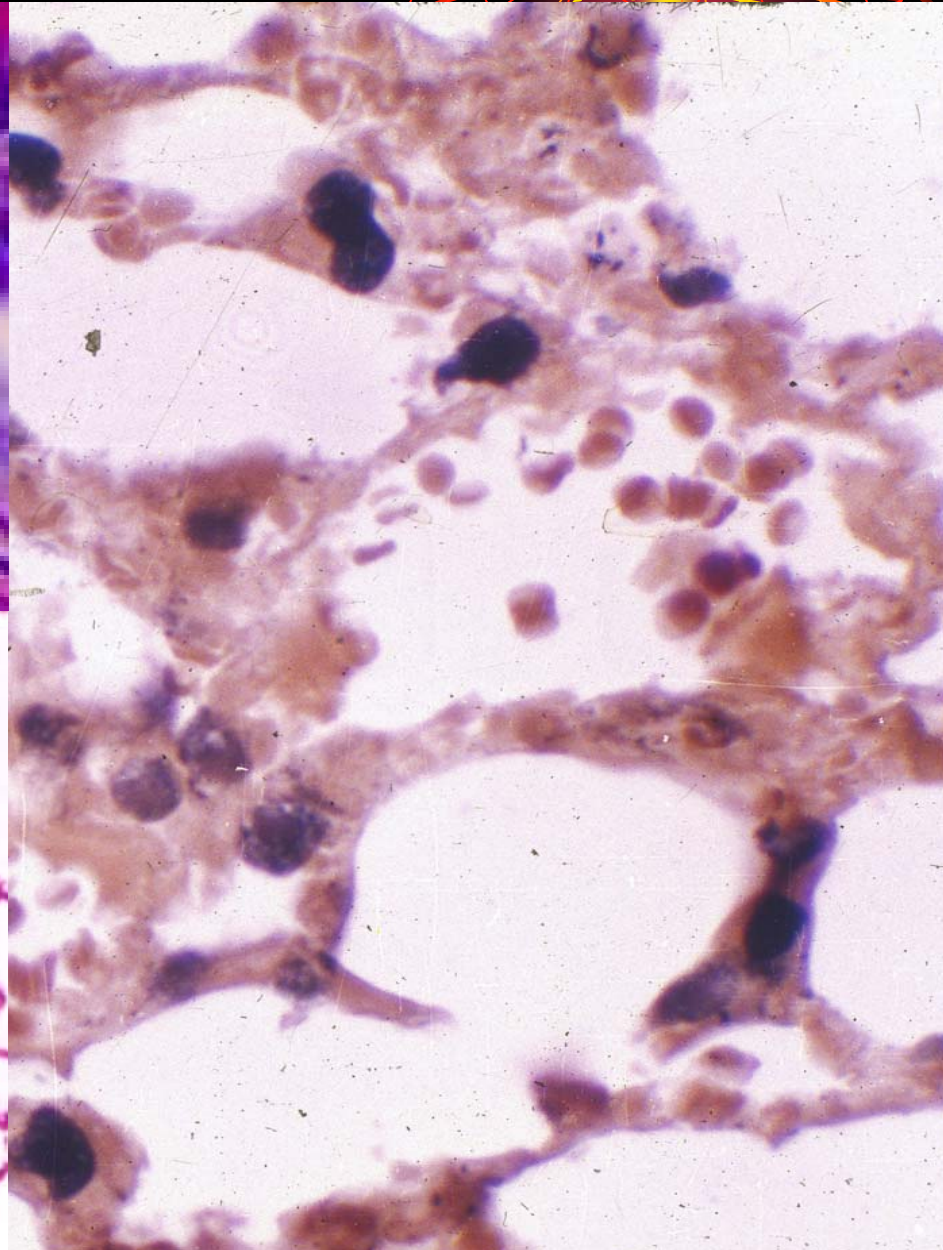
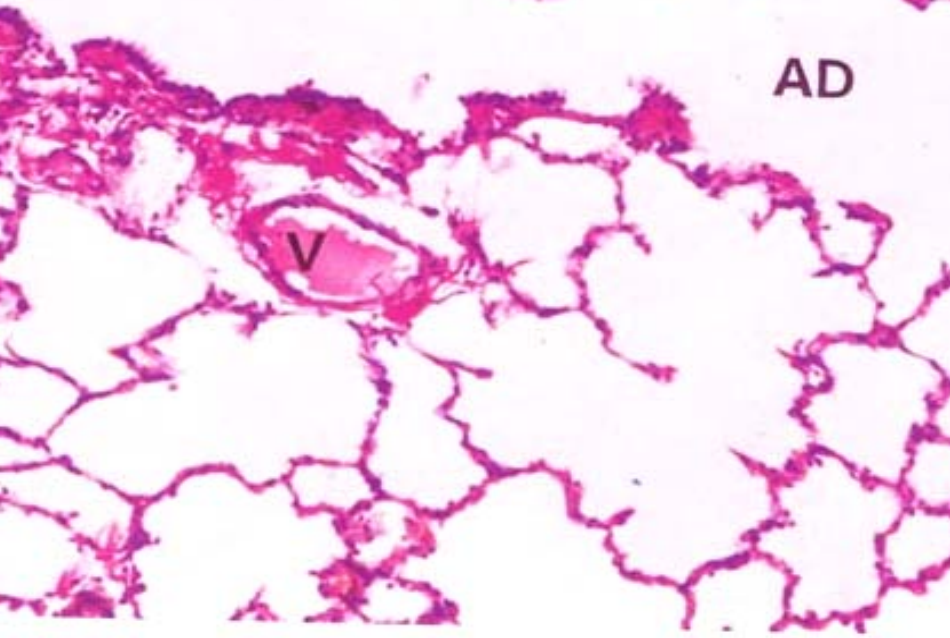
- **the combination of these layers is known as the blood-air barrier. The total thickness of these layers varies from 0.1 micrometer to 1.5 micrometer. It is at the blood-air barrier that gaseous exchange takes place between the air in the alveolar lumen and the blood within the capillary, O₂ from the alveolar air passes into the capillary blood through the blood-air barrier; CO₂ diffuses in the opposite direction. The approximately 300 million alveoli in the lungs considerably increase their internal exchange surface, which has been calculated to be approximately 140 m².**







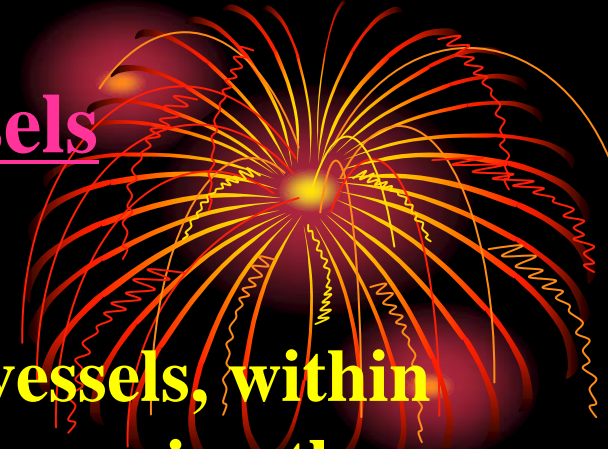3.2.5 Pulmonary Interstitium

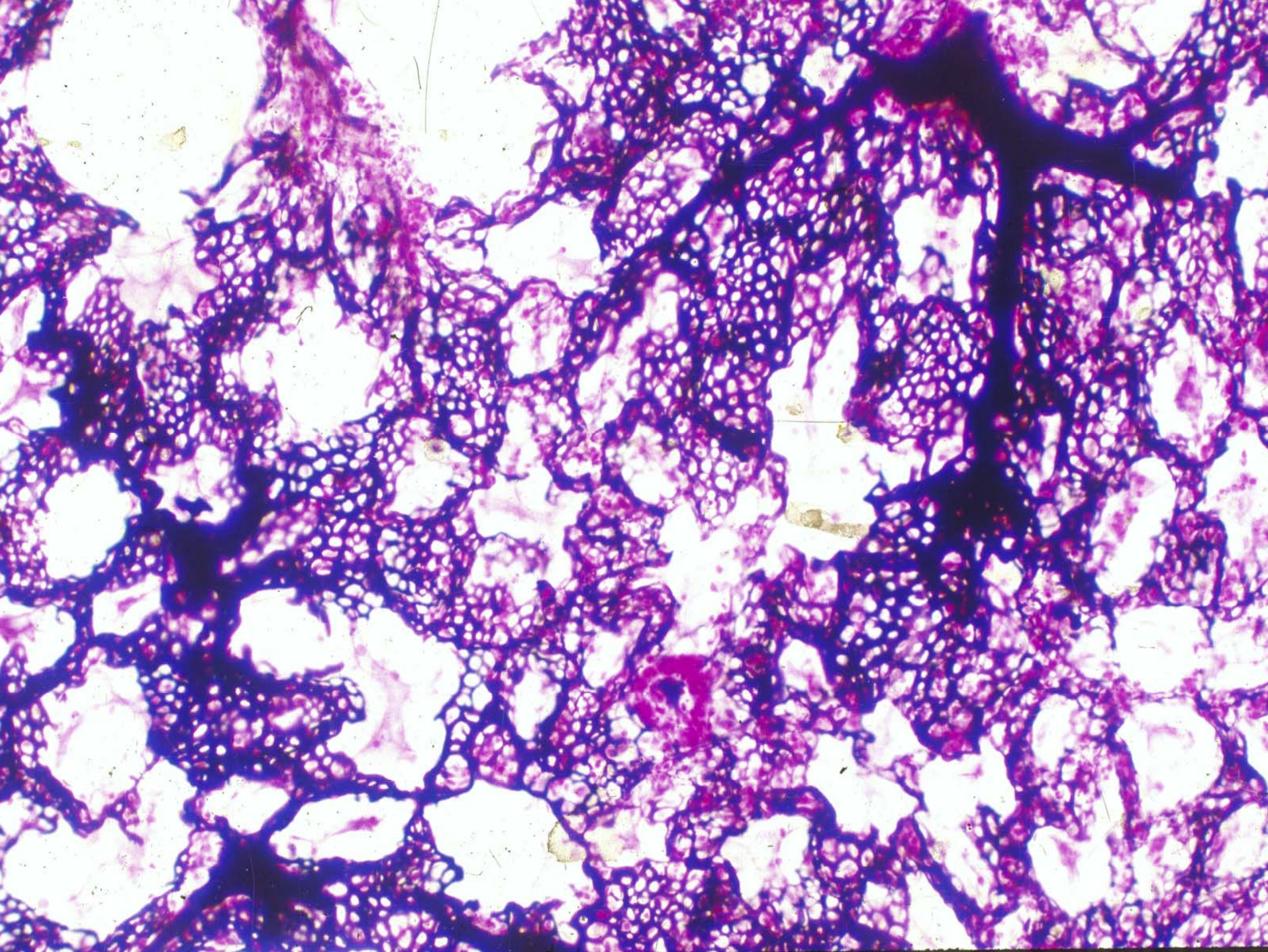


3.2.6 Pulmonary Blood Vessels


Pulmonary artery: functional blood vessels, within the lung this artery branches, accompanying the bronchial tree, at the level of the alveolar duct, the branches of this artery form a capillary network in close contact with the alveolar epithelium.

Bronchial artery: nutrient blood vessels, the branches of the bronchial artery also accompany the bronchial tree, but only to the respiratory bronchioles, at which point they anastomose with the pulmonary artery.





summary



- the general structure of trachea
- the conducting portion and the respiratory portion
- the alveolar epithelium
- the blood-air barrier