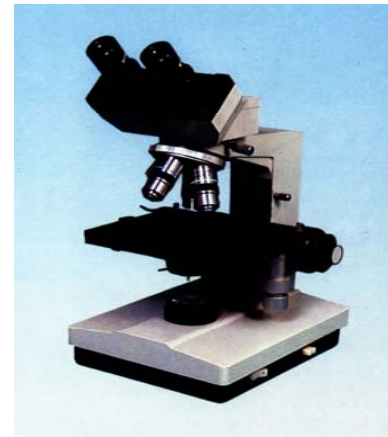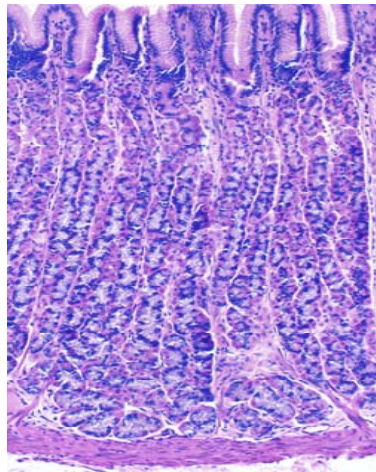



Experimental Courseware of Histology and Embryology



Chapter 1 Introduction and Cell

Chapter 2 Epithelial tissue

Chapter 3 Connective Tissue

Chapter 4 Blood

Chapter 5 Cartilage and Bone

Chapter 6 Muscle Tissue

Chapter 7 Nerve Tissue

Chapter 8 Circulatory System

Chapter 9 Immune System

Chapter 10 Skin

[Chapter 11 Digestive Tract](#)

Chapter 12 Digestive Gland

Chapter 13 Respiratory System

Chapter 14 Urinary System

Chapter 15 Endocrine System

Chapter 16 Sense Organs

Chapter 17 Male Reproduction

Chapter 18 Female Reproduction

Chapter 19 Embryology 1

Chapter 20 Embryology 2

Chapter 11 Digestive Tract

I Slides

II Sections

NO.55 esophagus

NO.56 stomach

NO.59 jejunum

NO.60 ileum

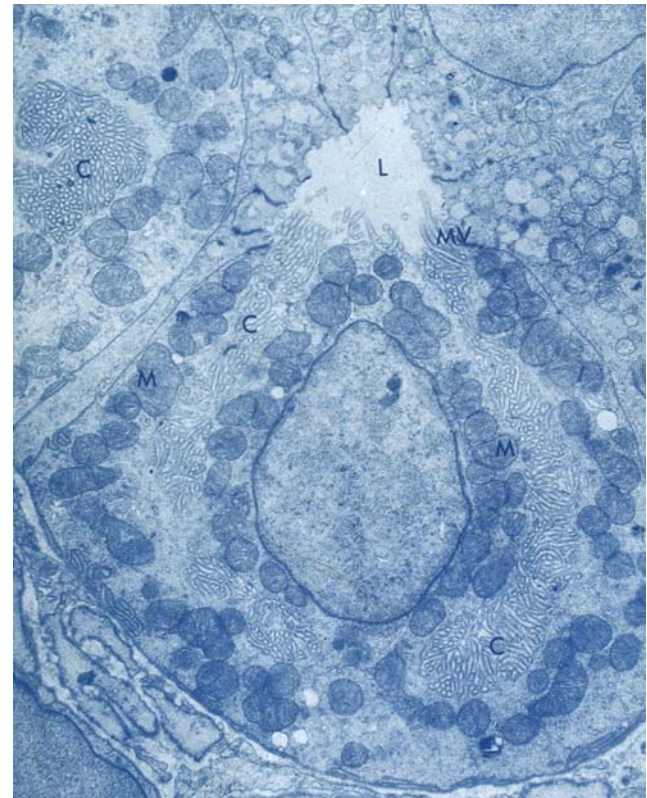
NO.58 duodenum

NO.61 colon

NO.62 appendix

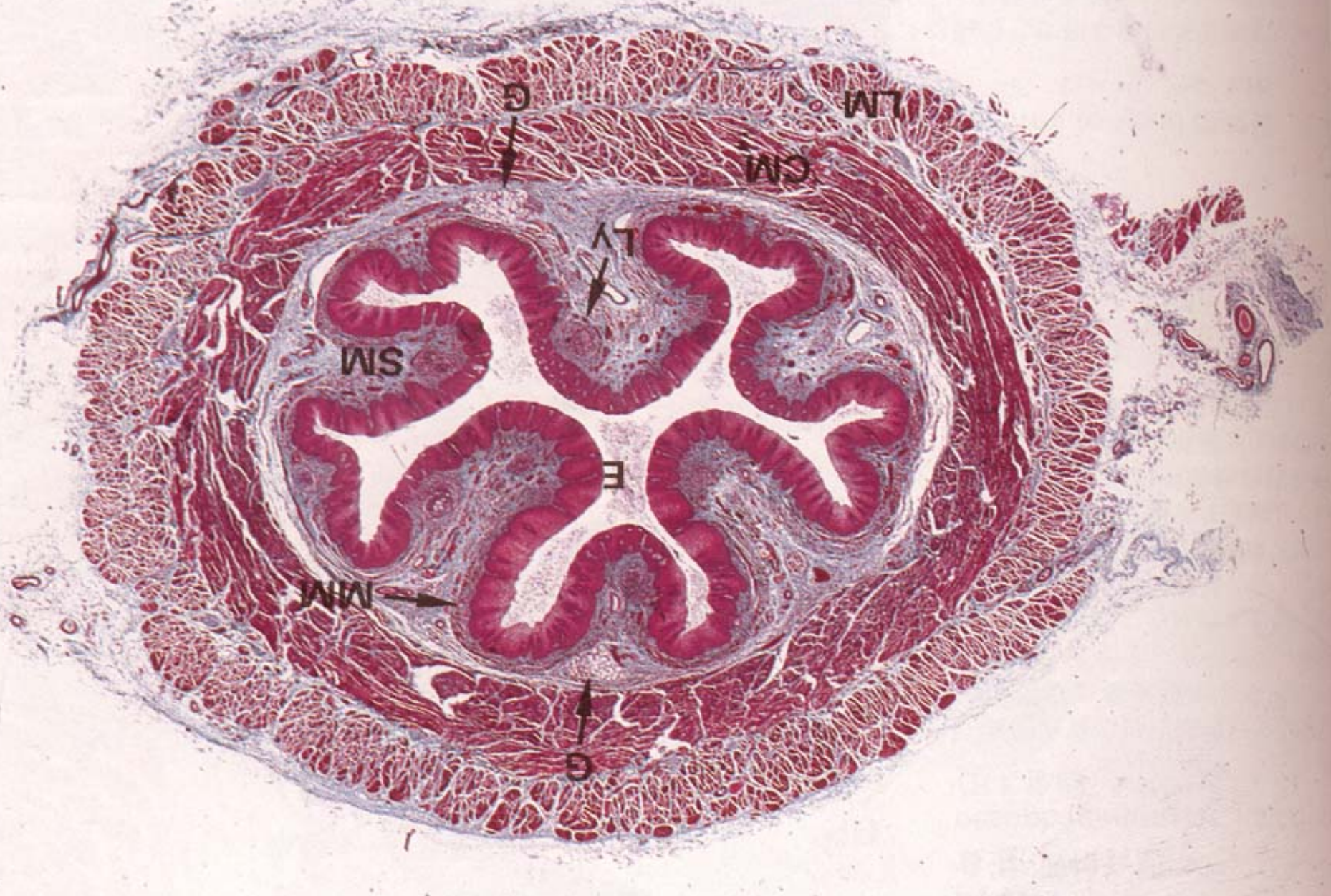III EM photos: 46, 49~51

IV Summary :

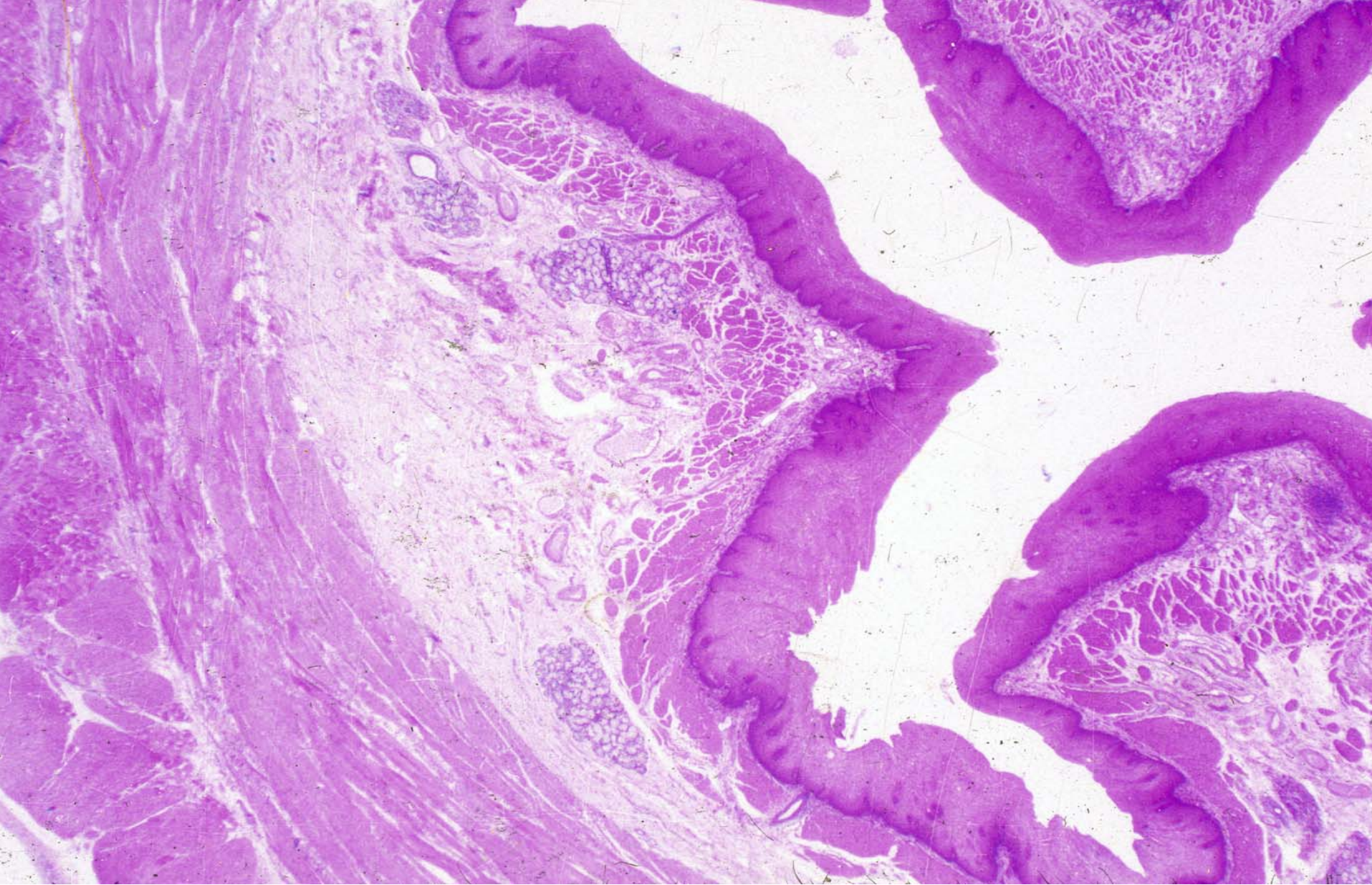


IV Summary

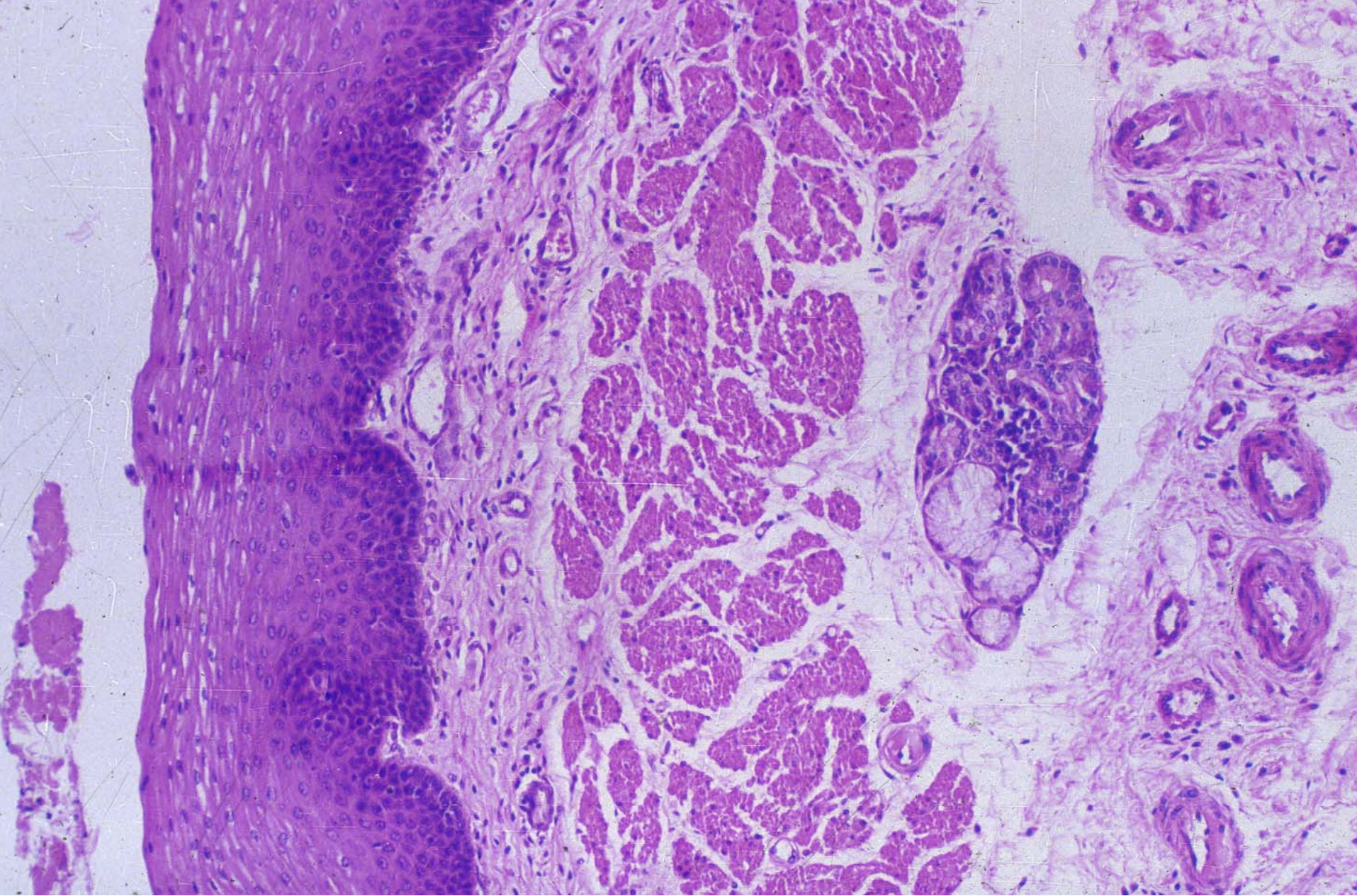
- 1. The general structure of digestive tract**
- 2. The structure of esophagus , stomach and small intestine**



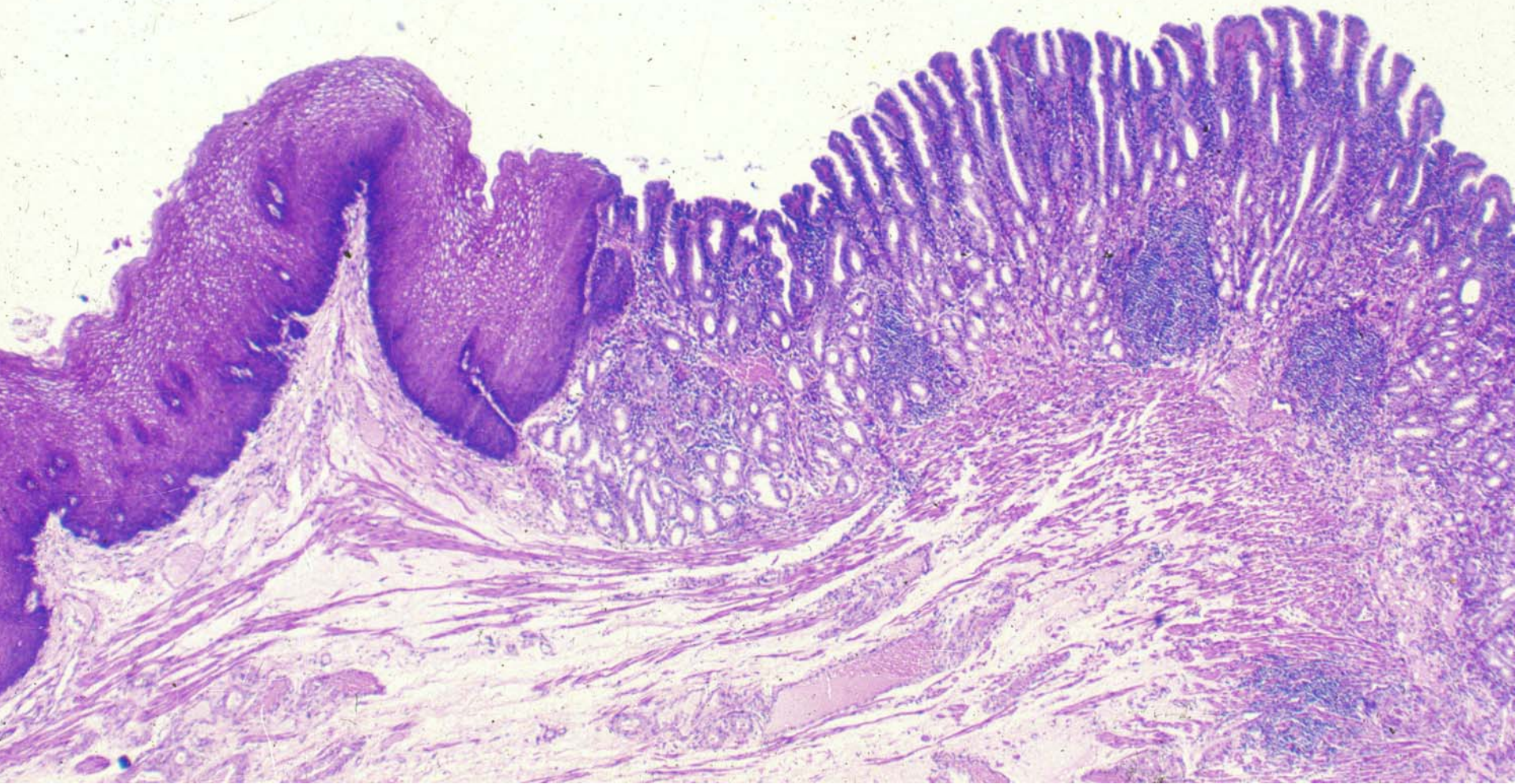
esophagus



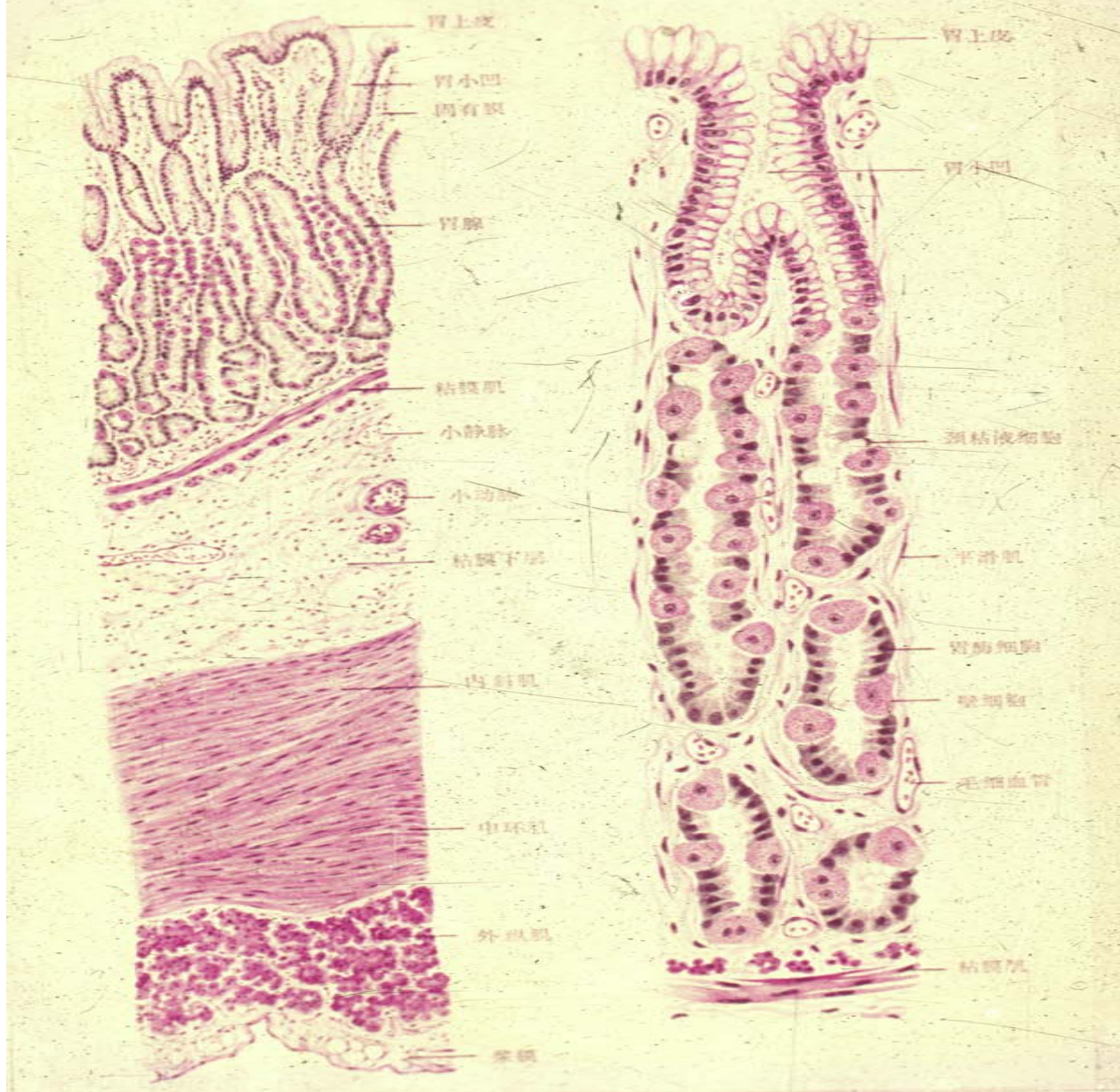
esophagus



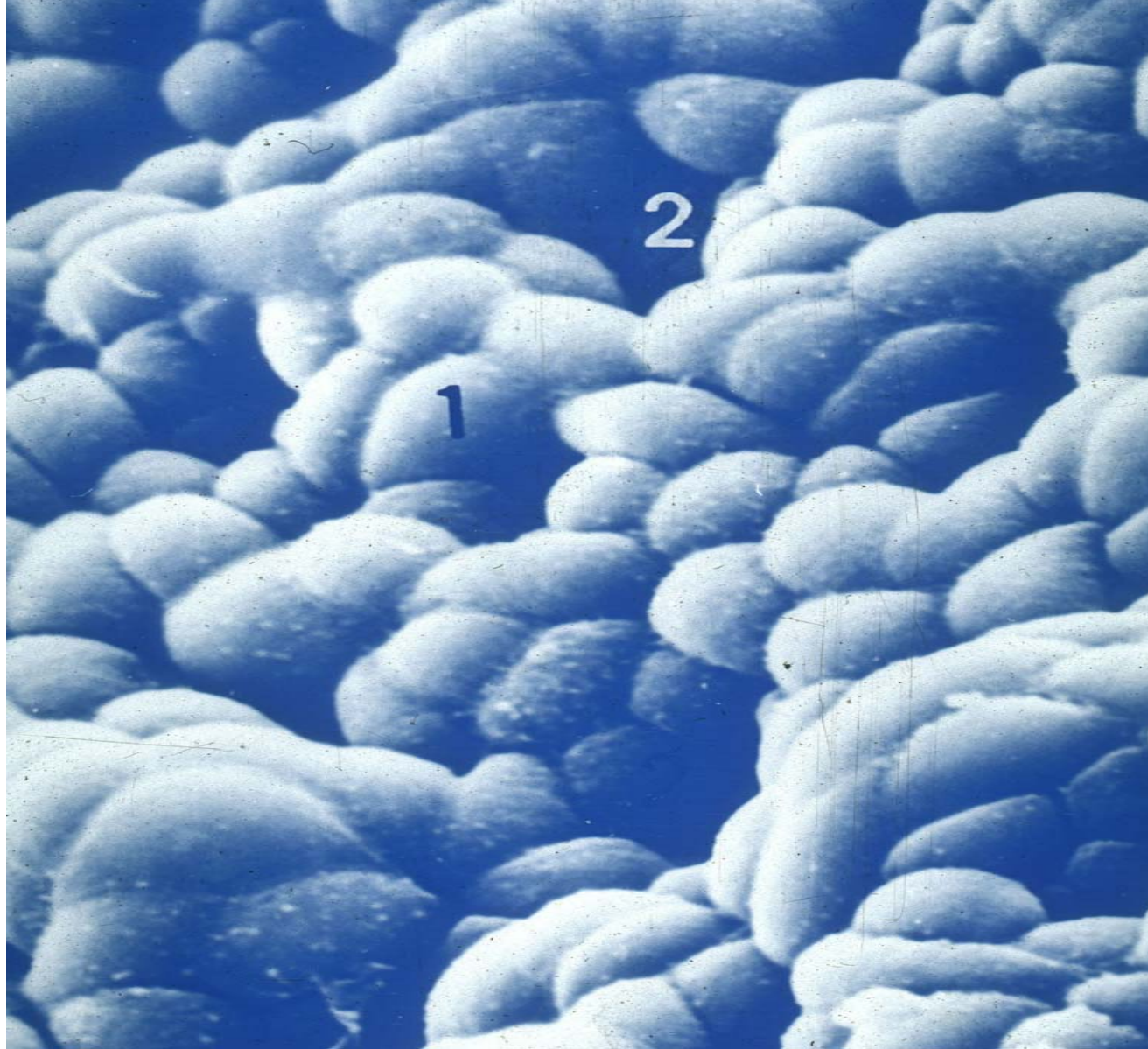esophagus



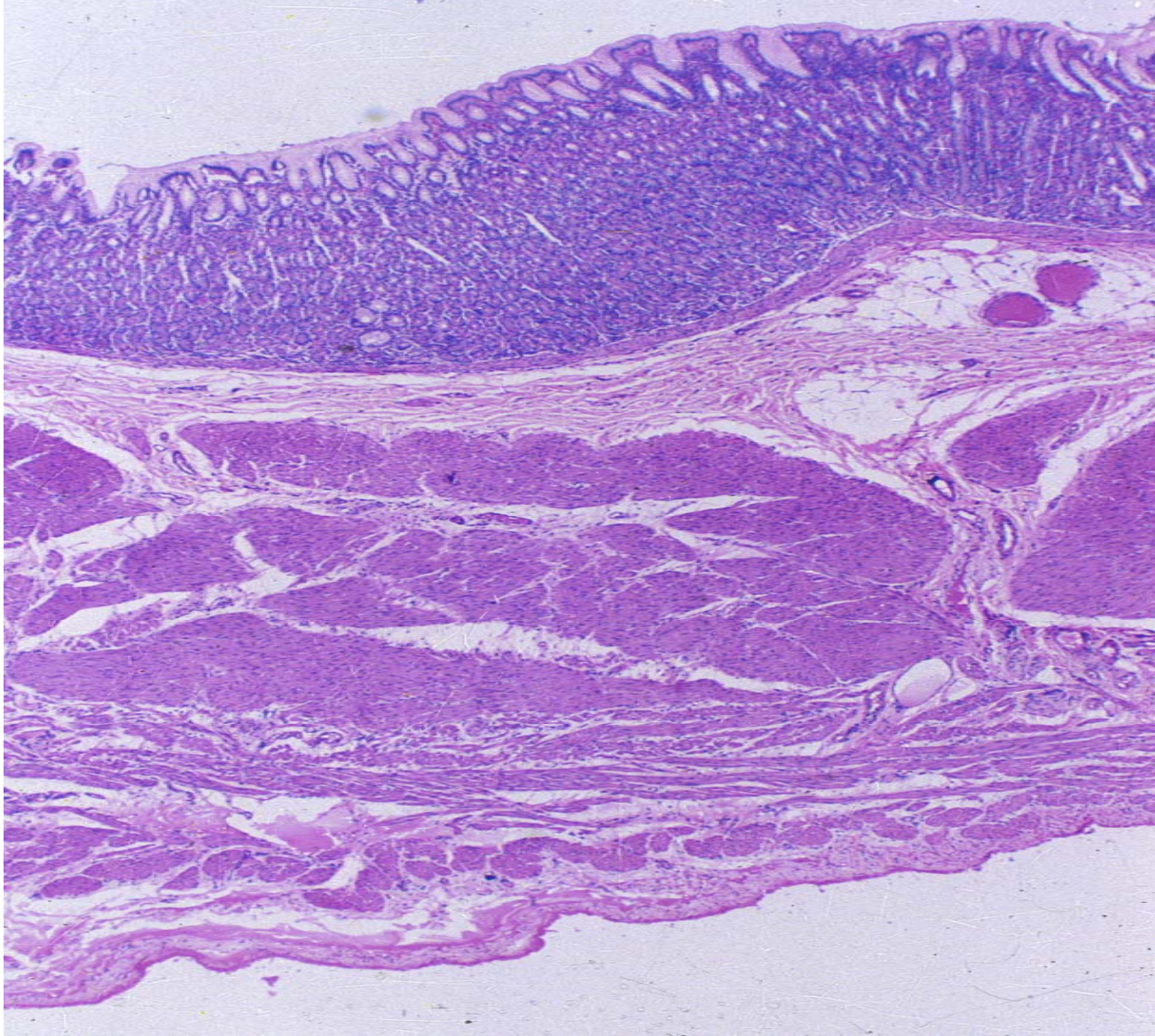Esophagus-pylorus



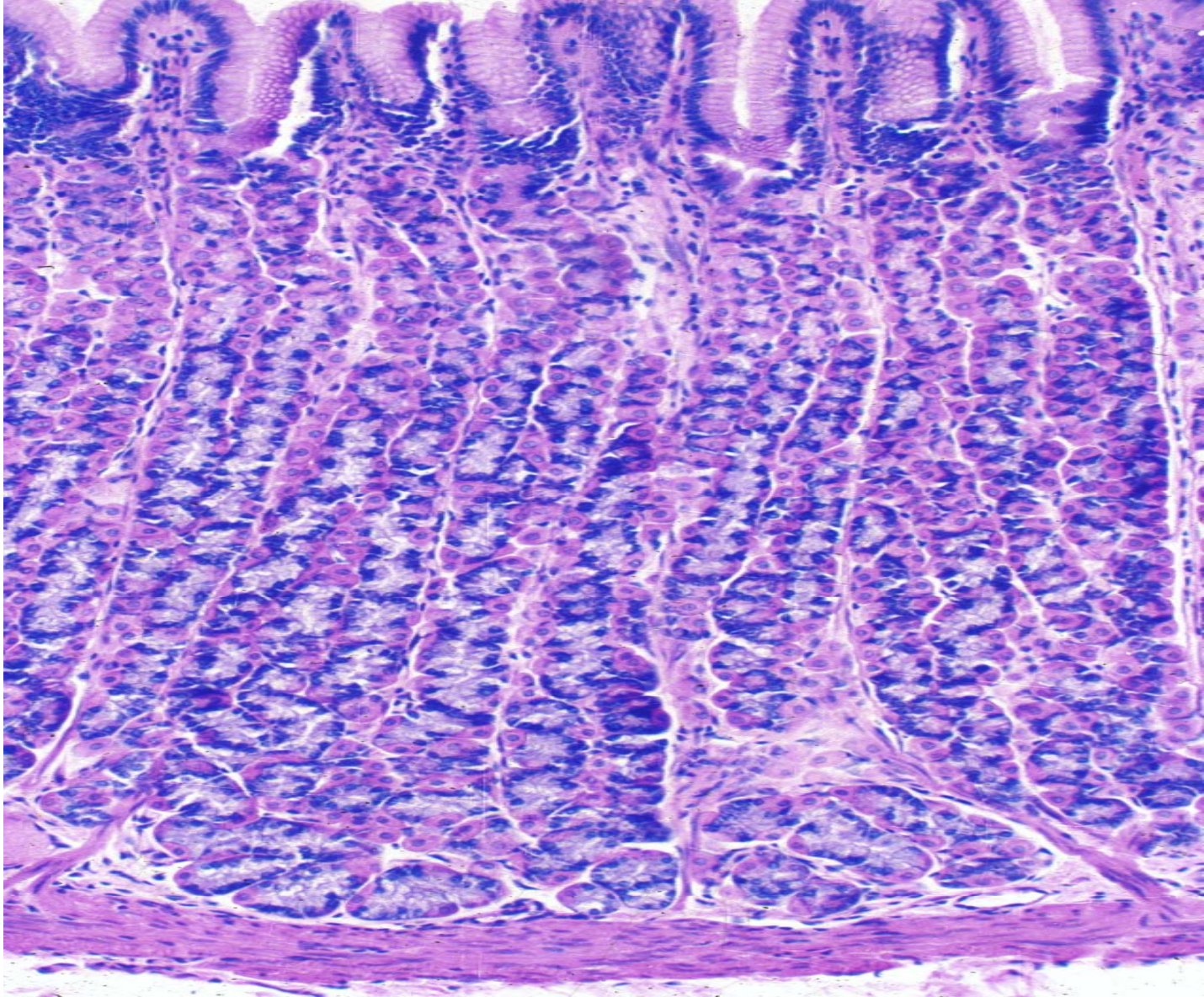
stomach



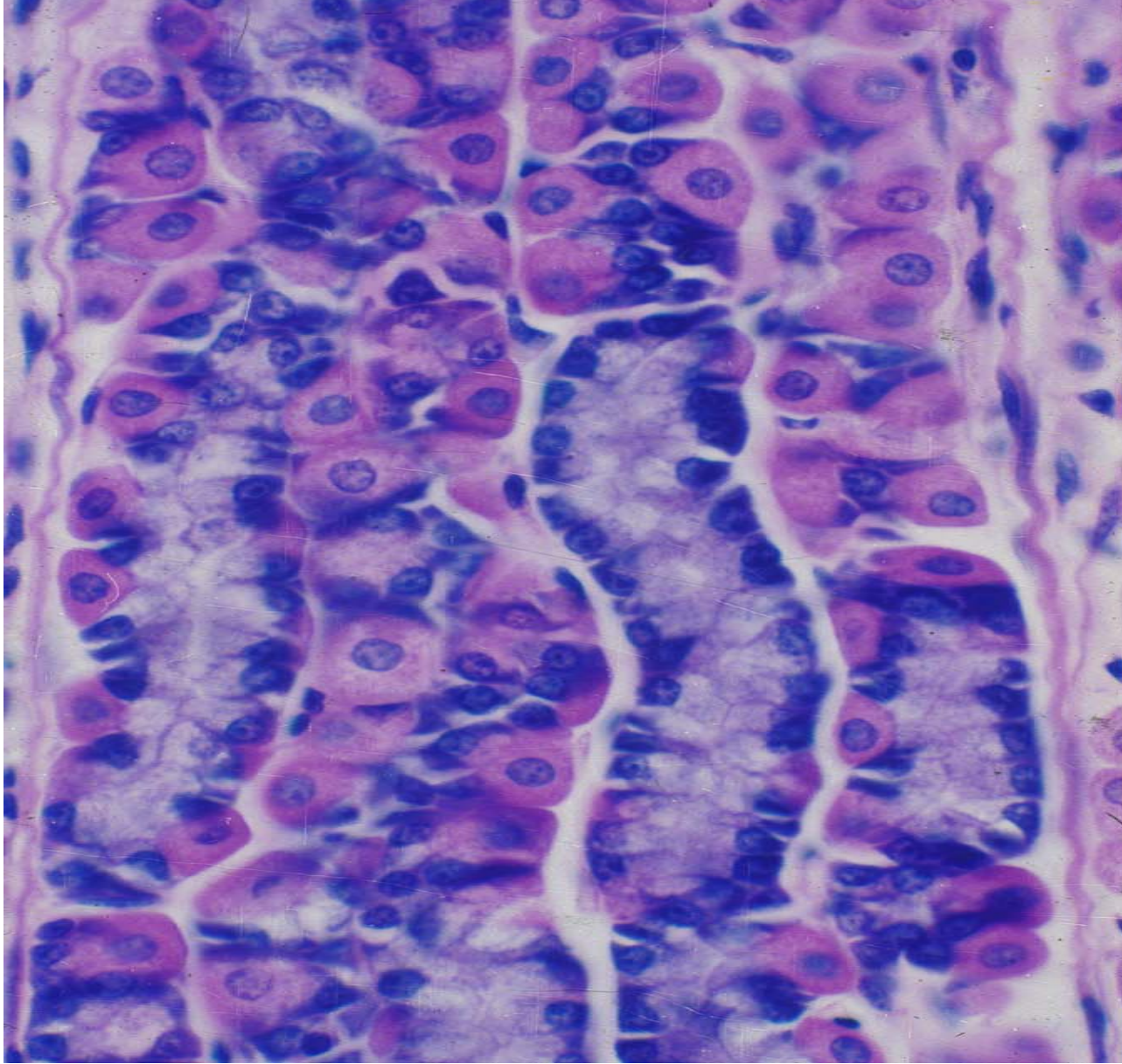
Gastric pit



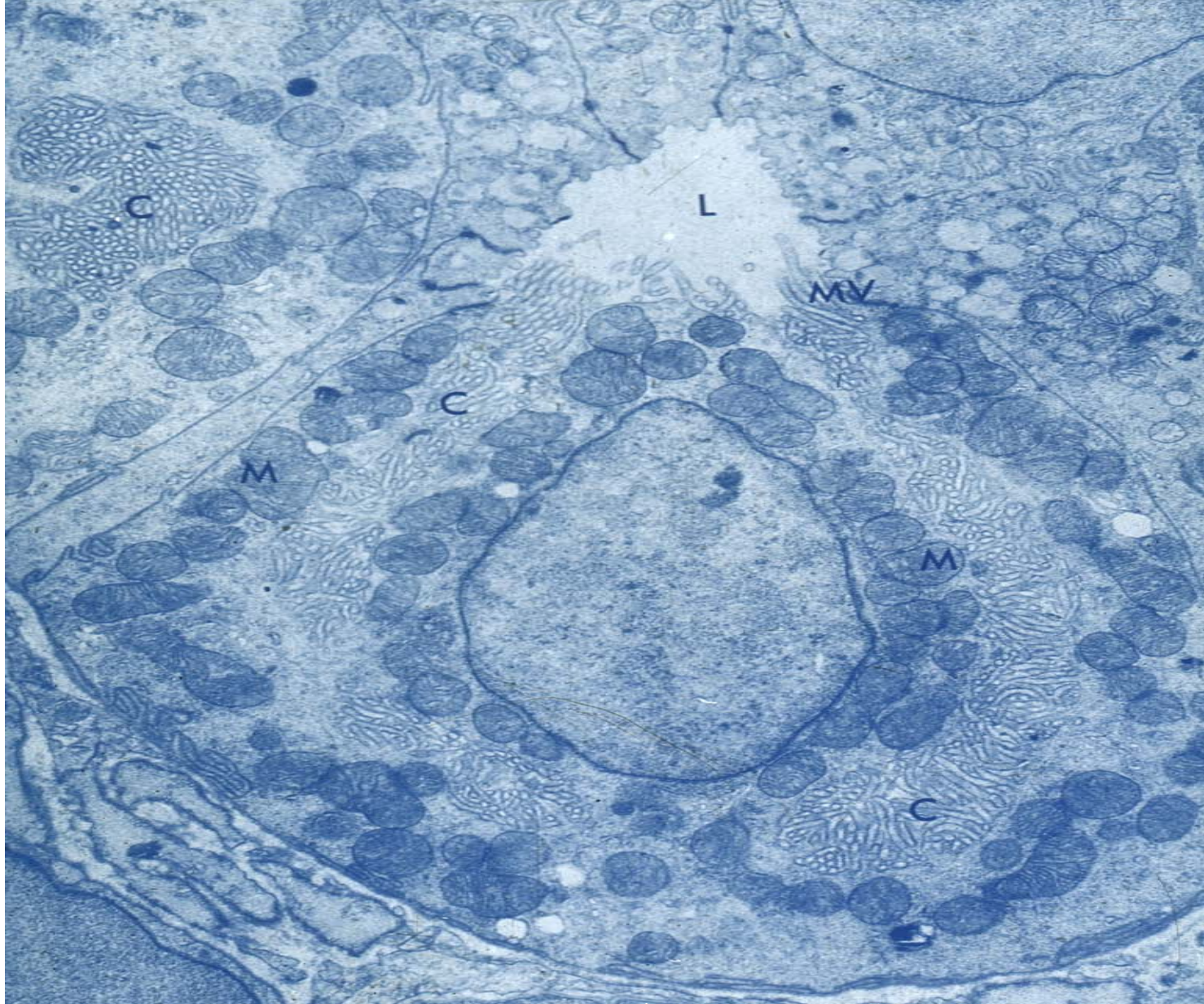
stomach



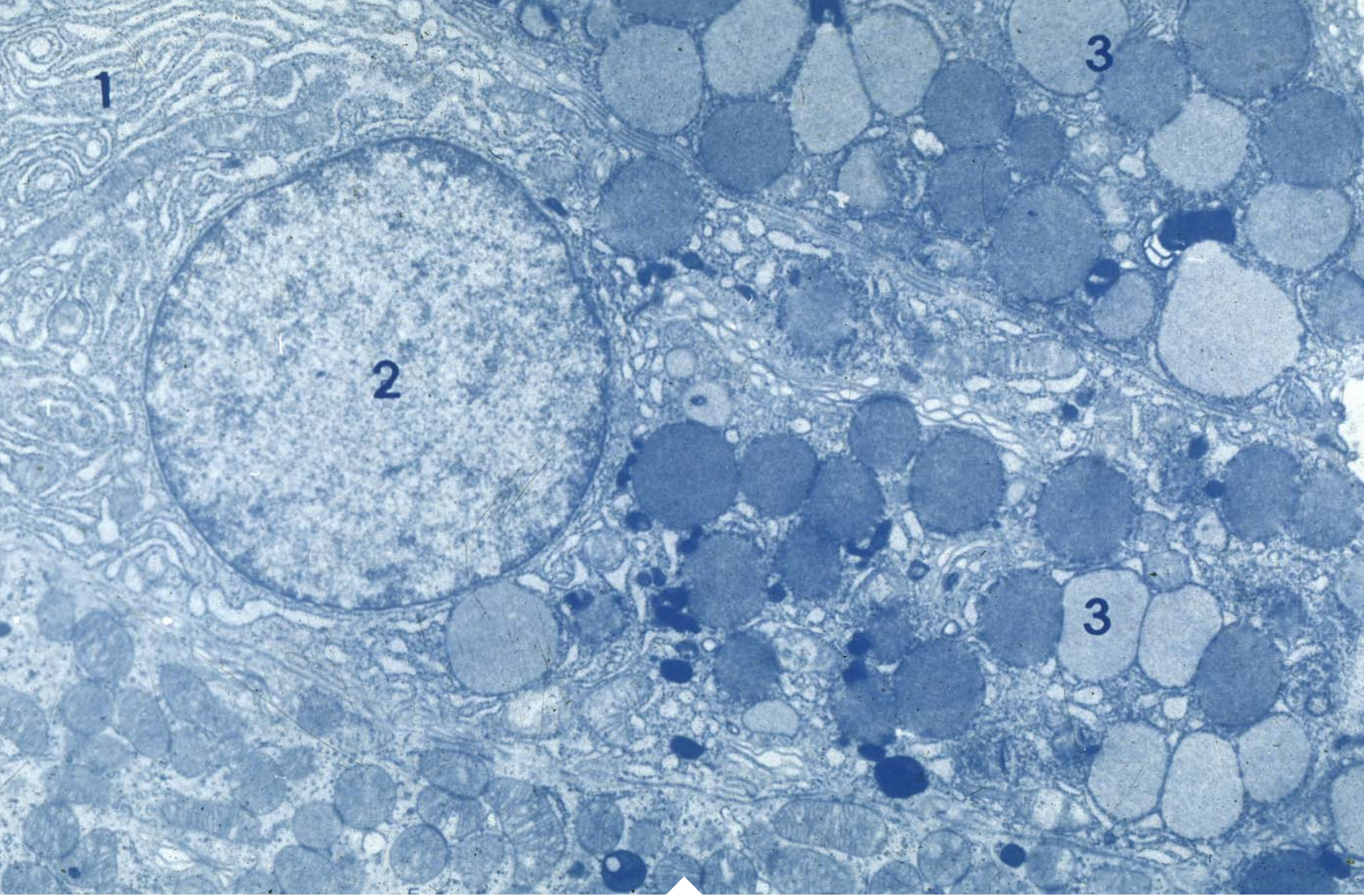
Tunica mucosa



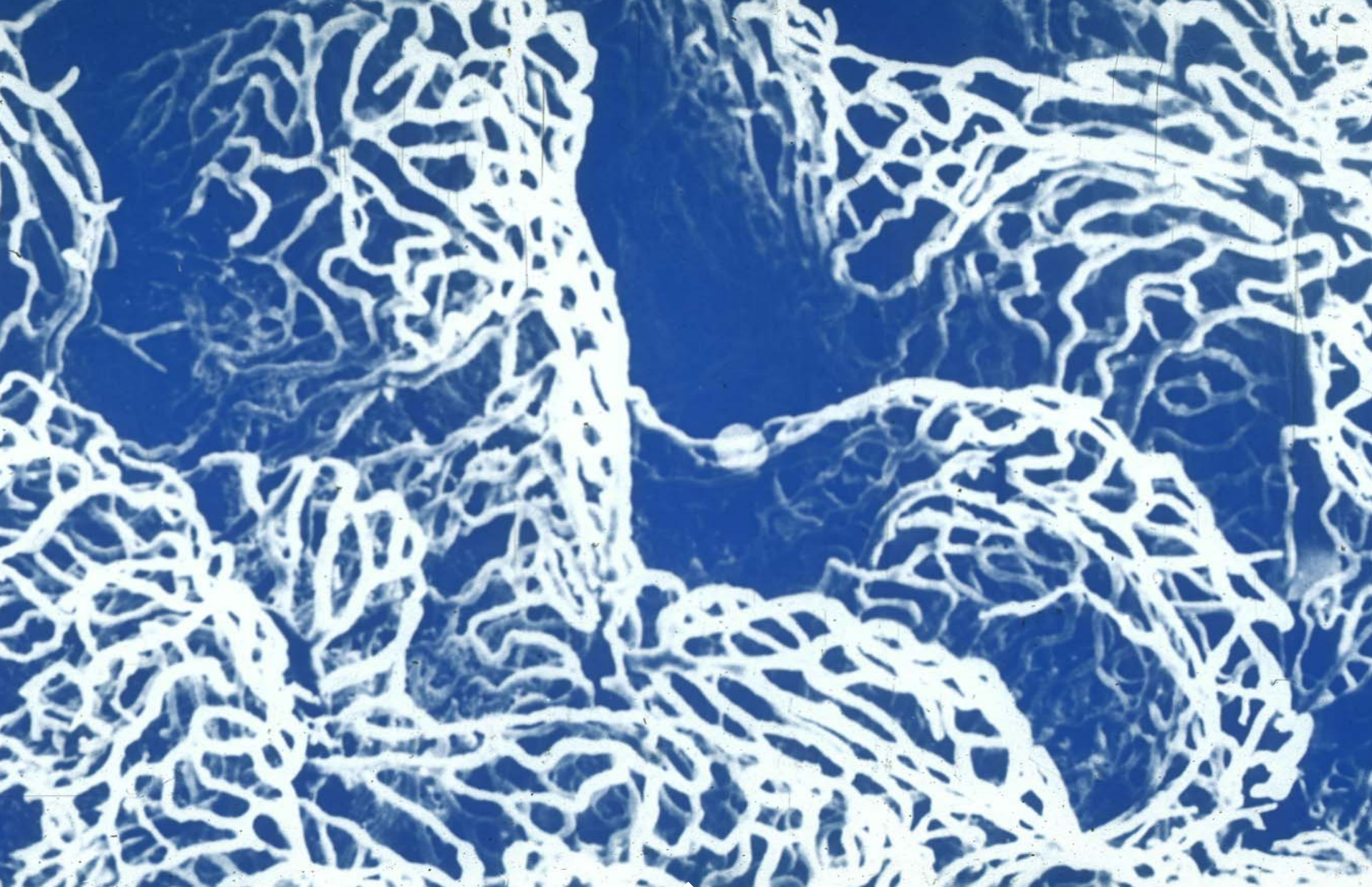
Fundic gland



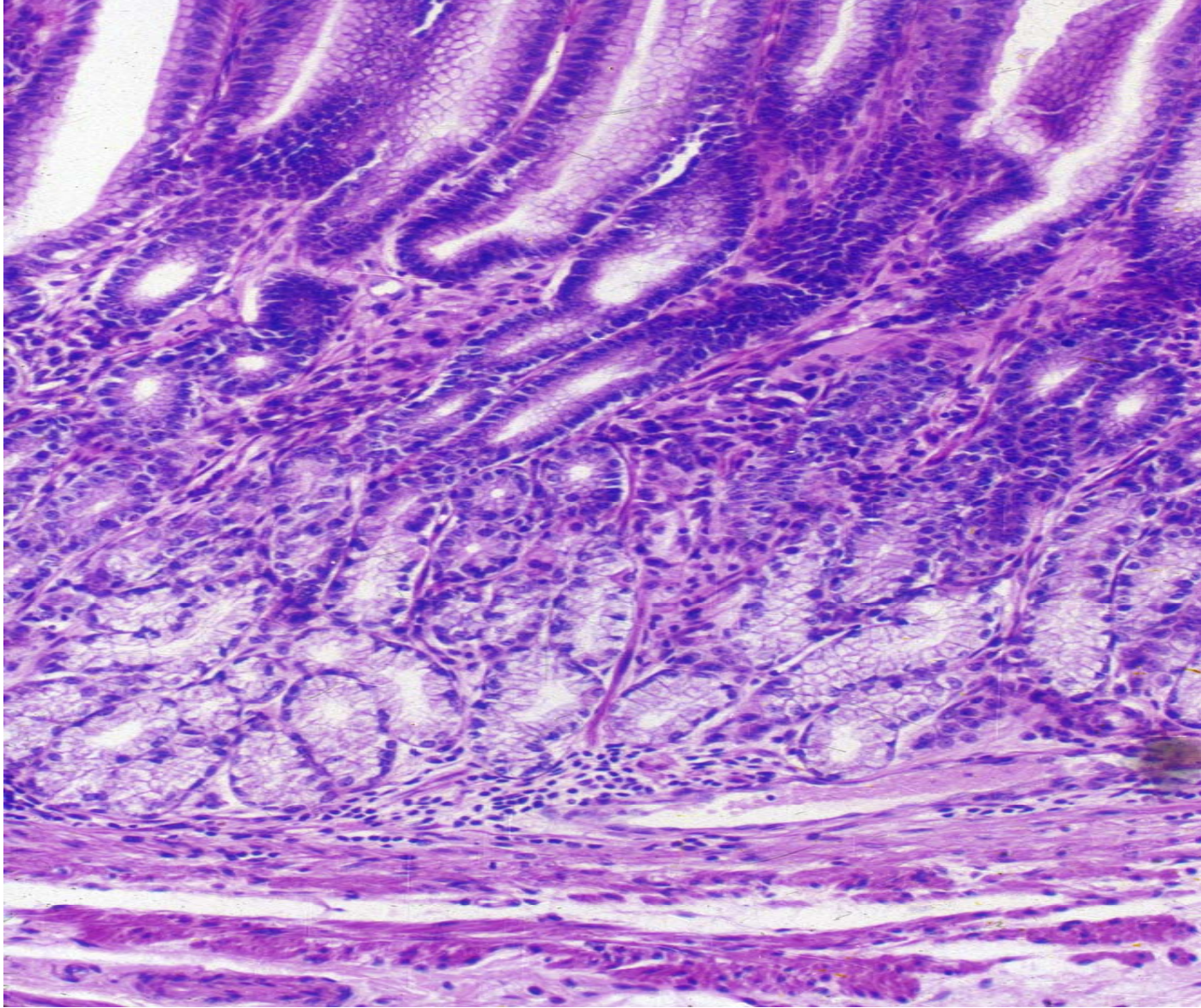
parietal cell



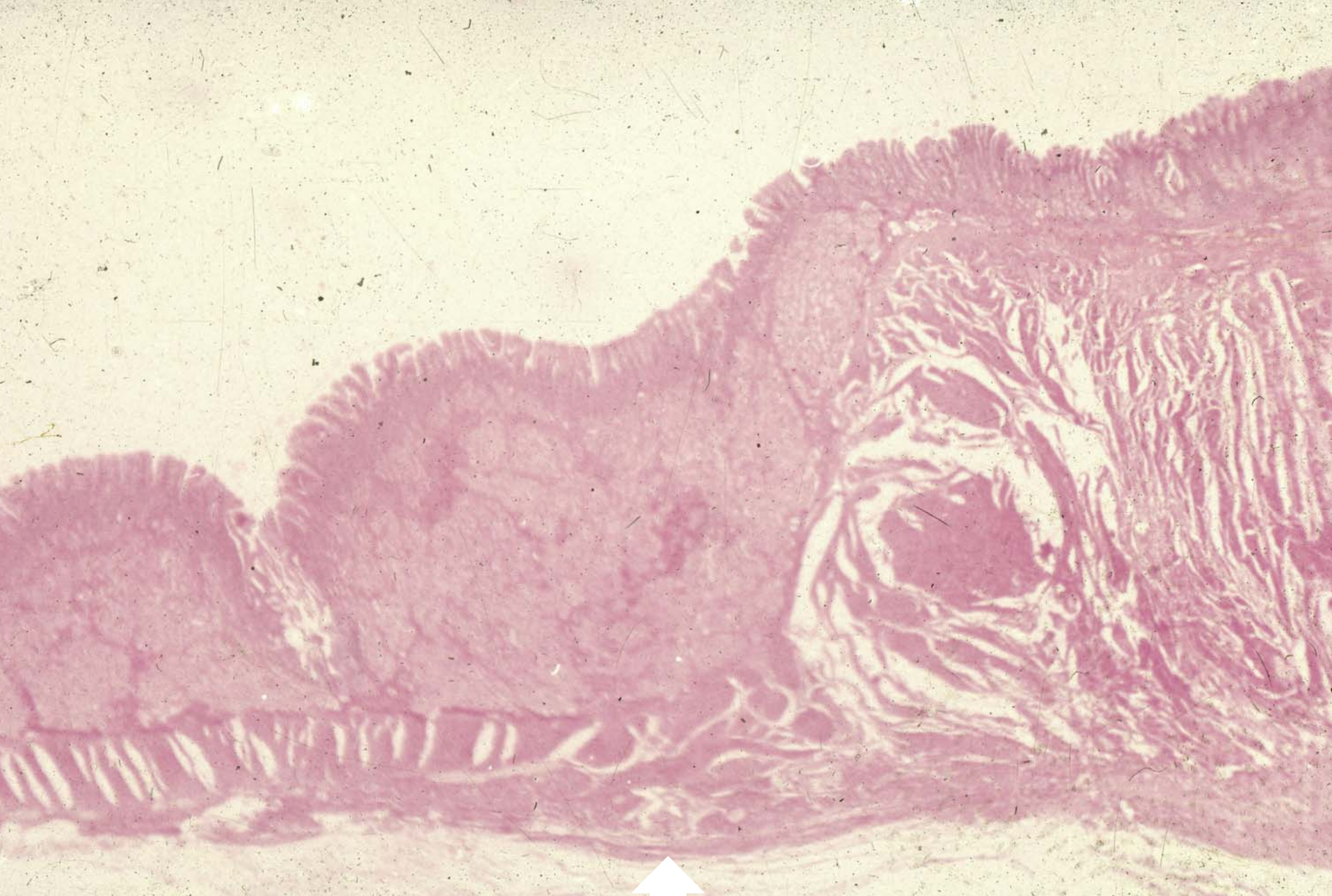chief cell



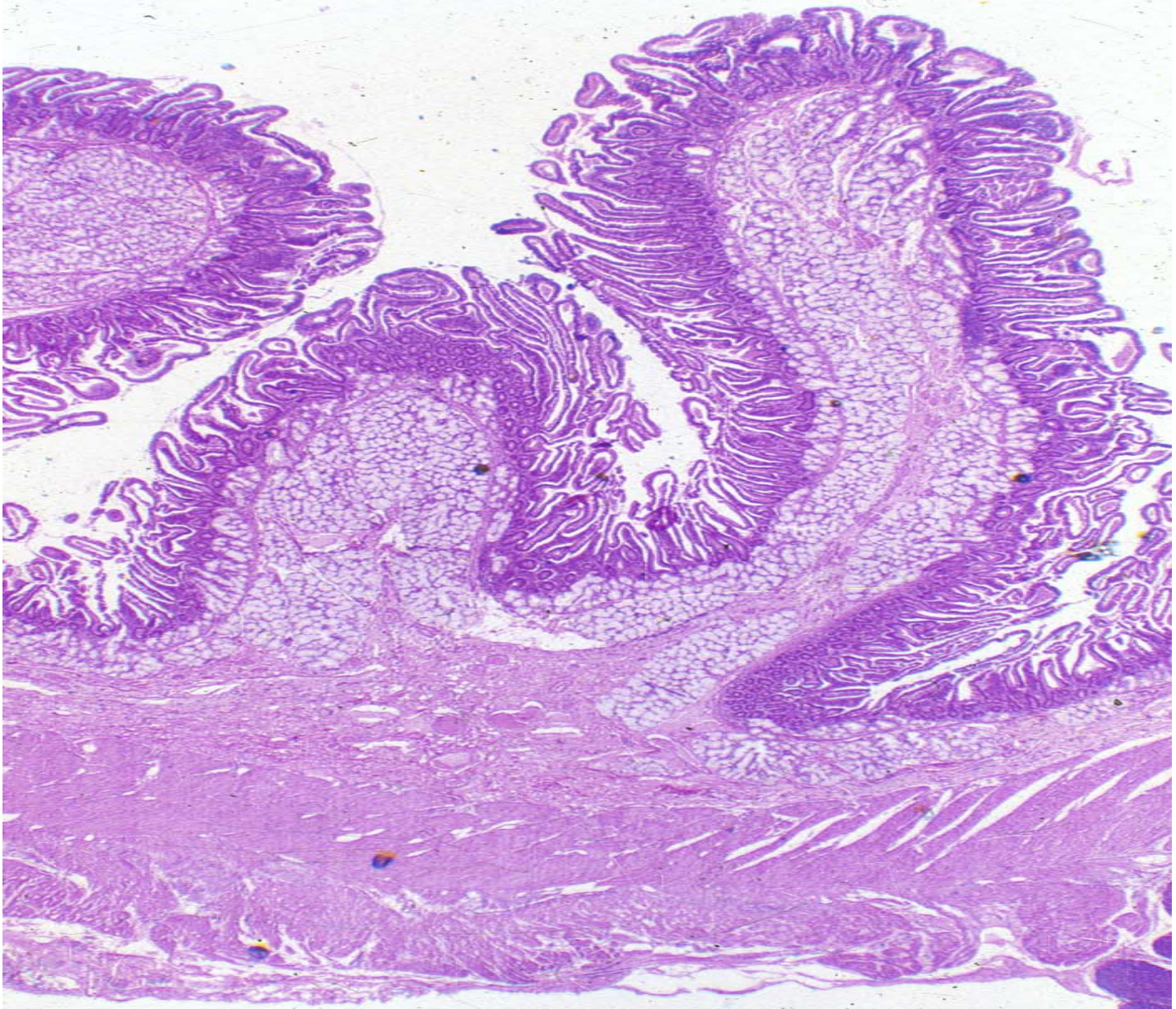
Intestinal mucosal capillary plexus



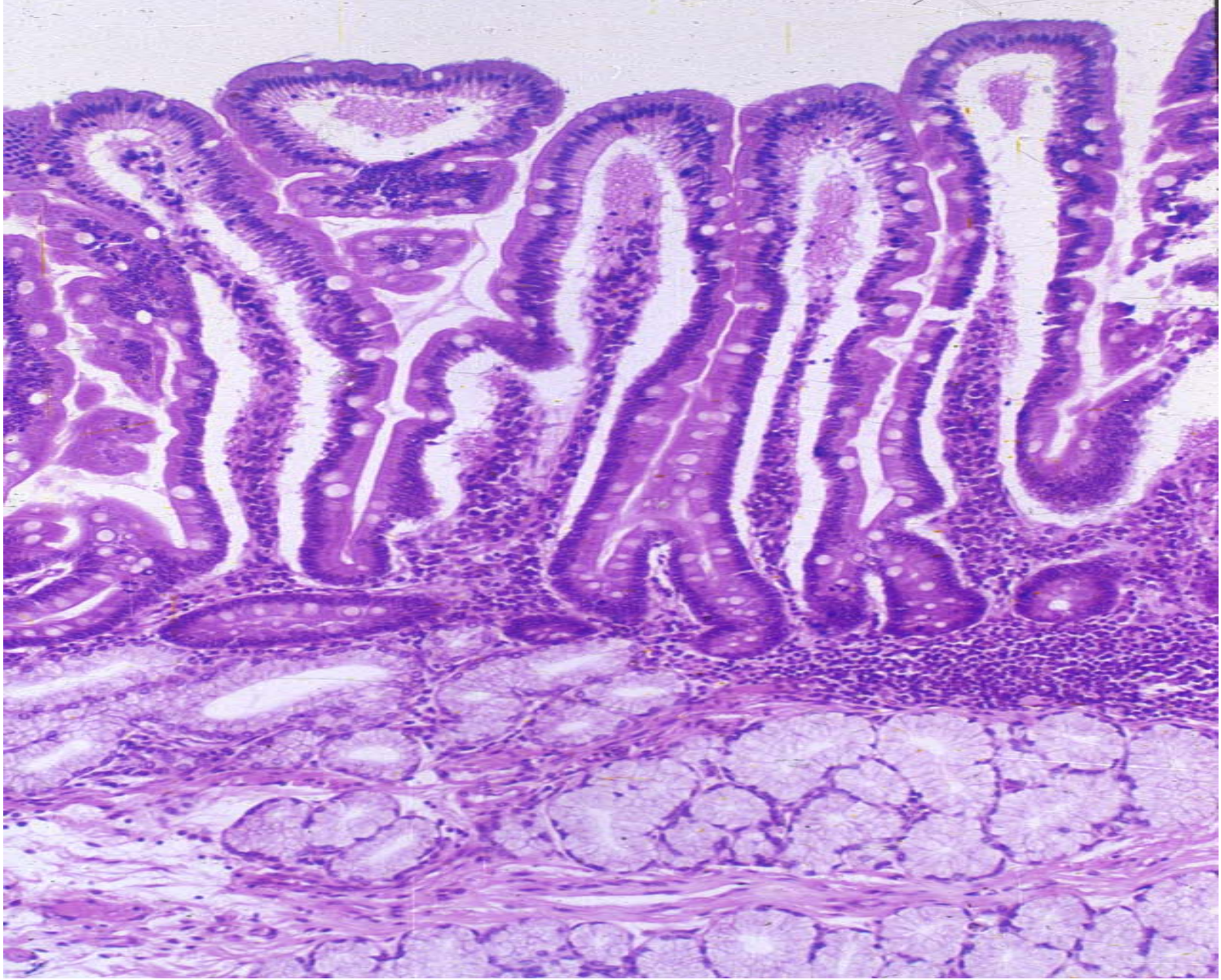
duodenum



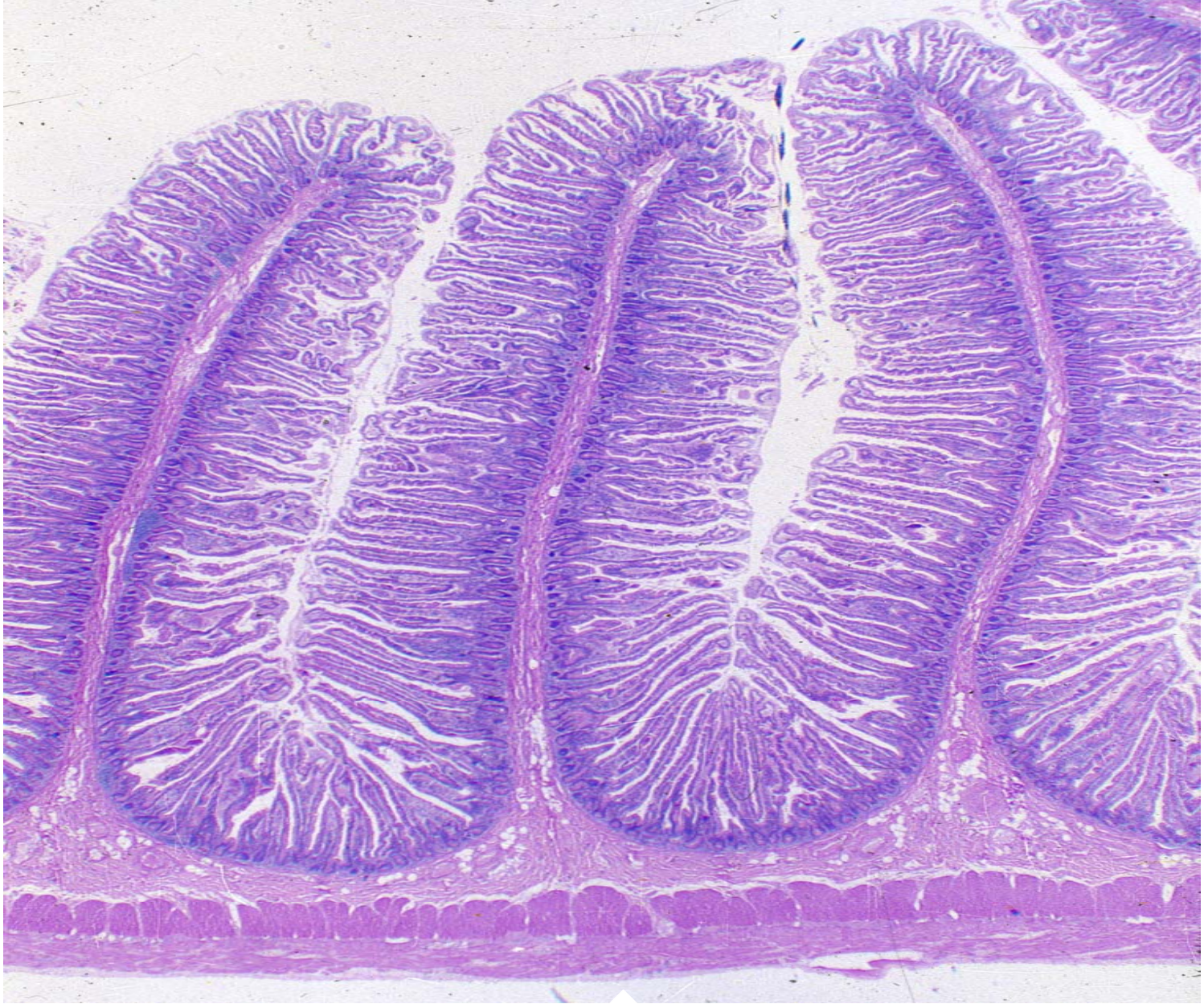
duodenum



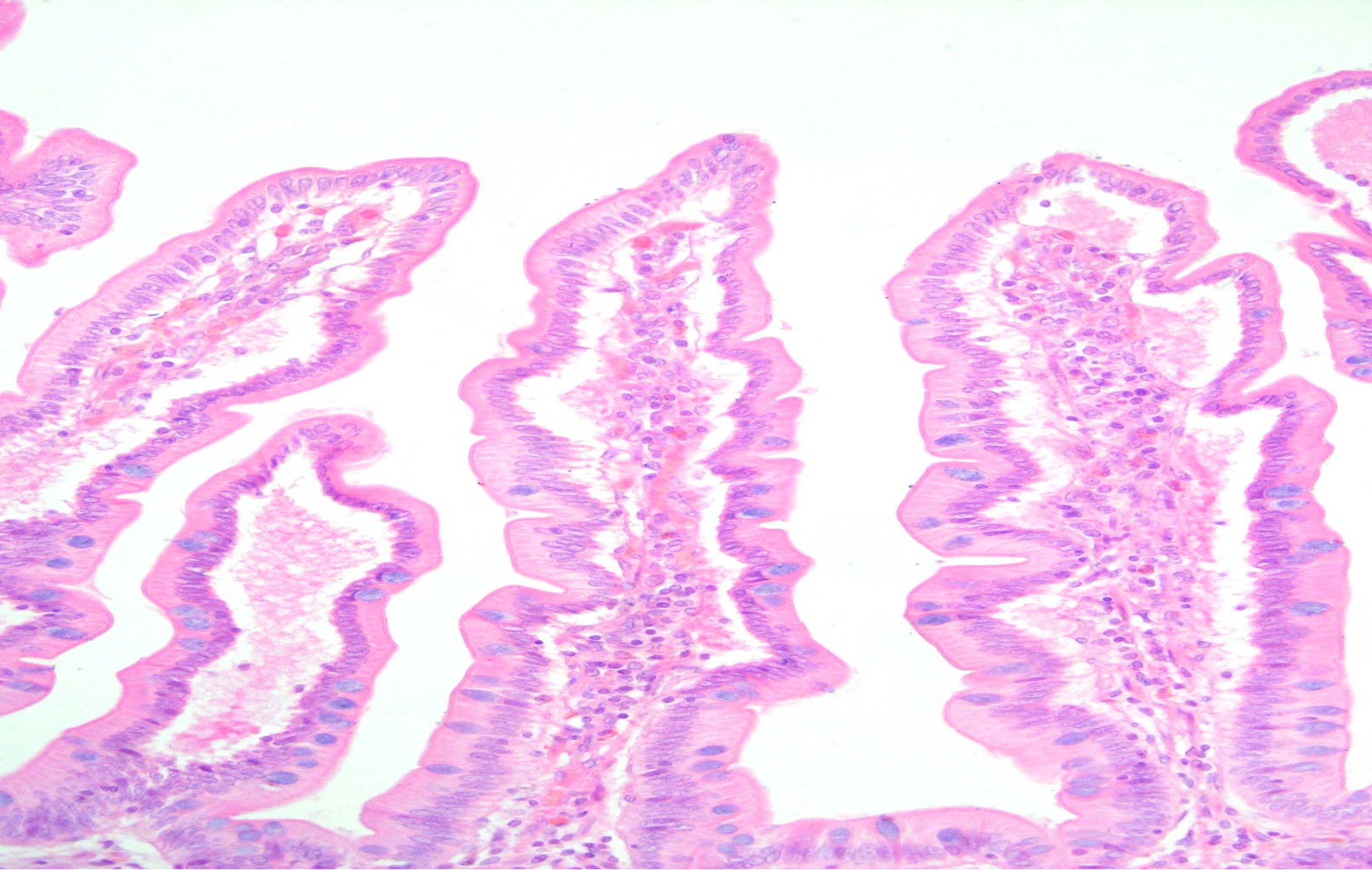
duodenum



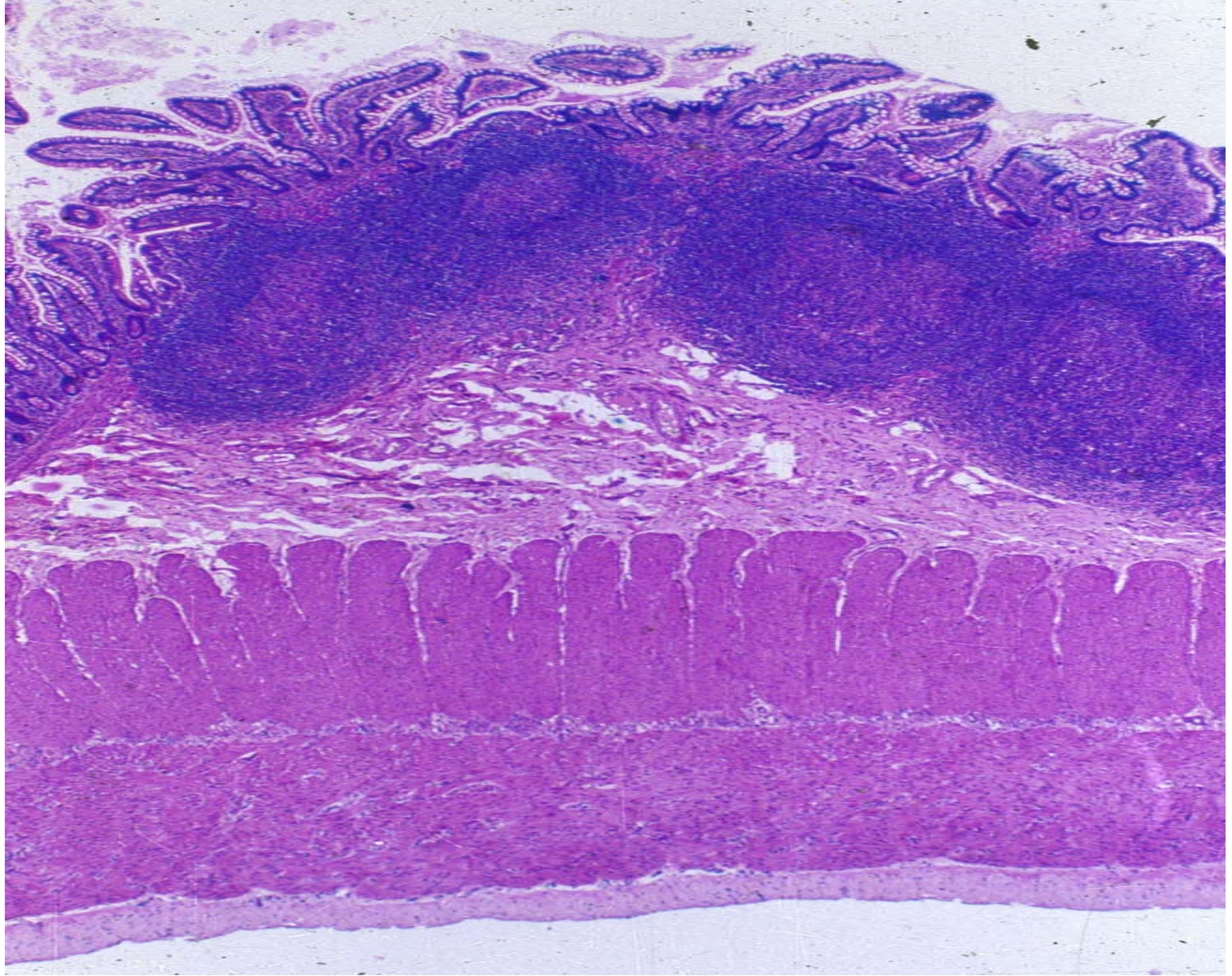
duodenum



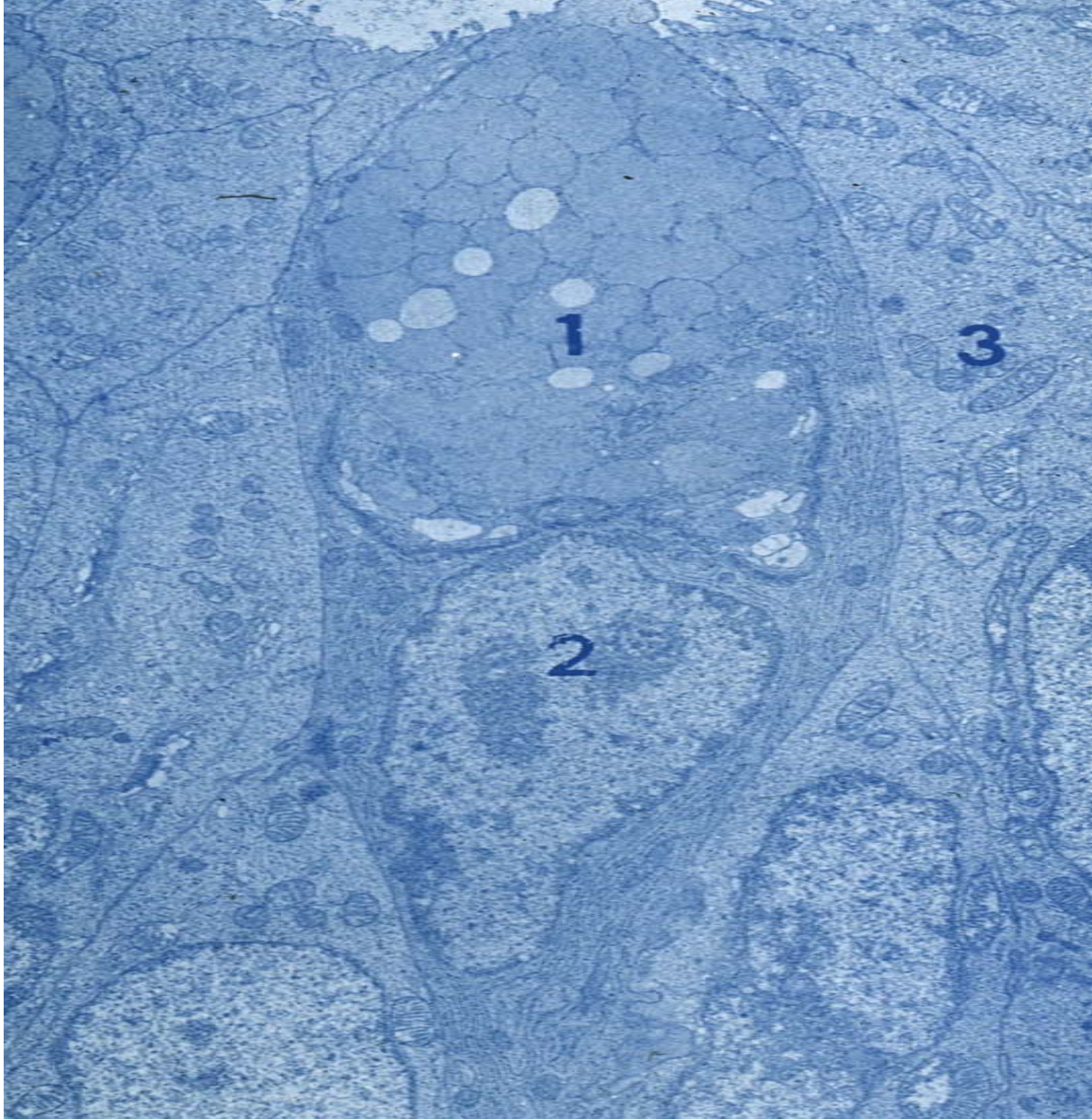
jejunum



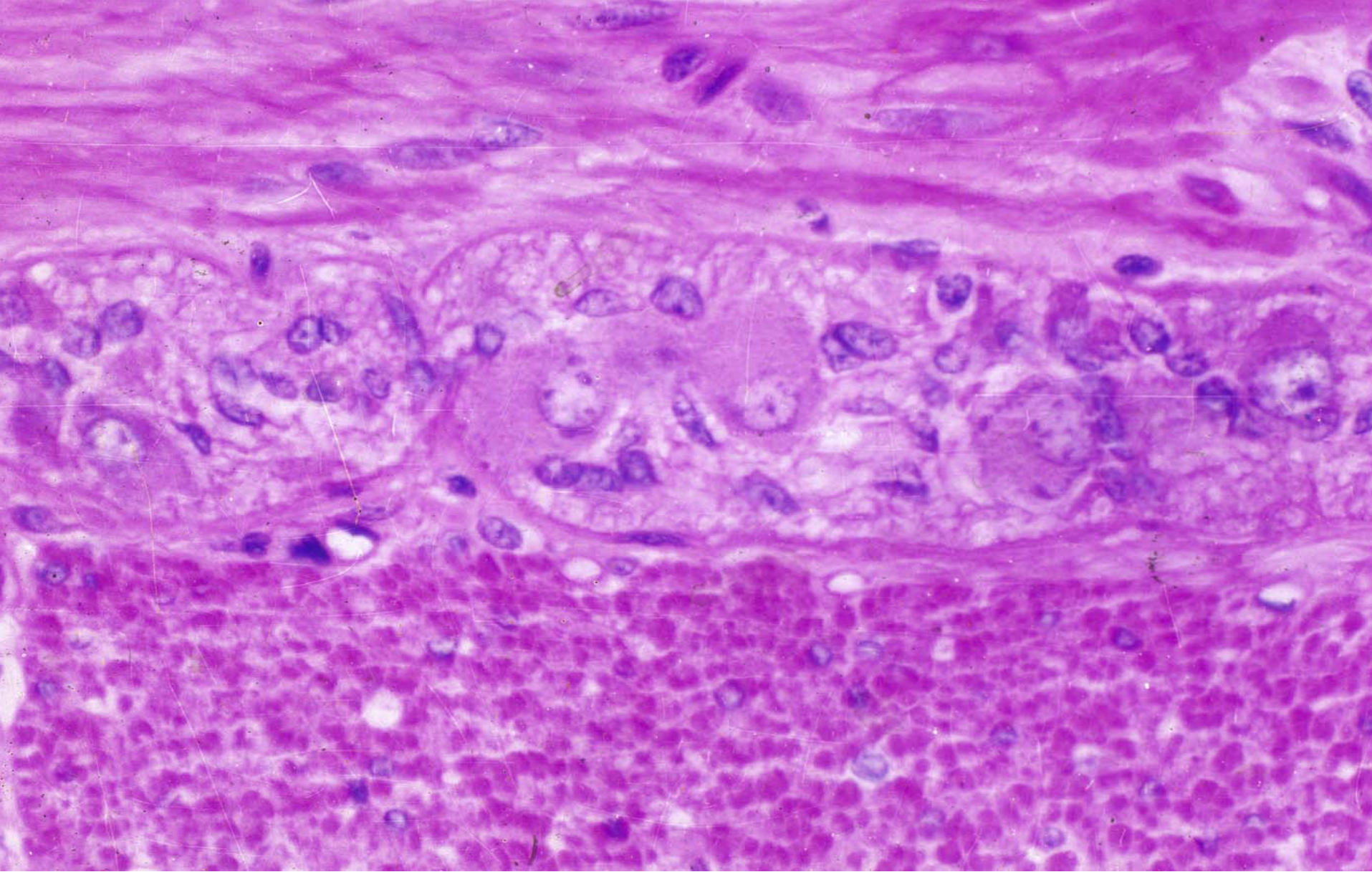
Intestinal villus



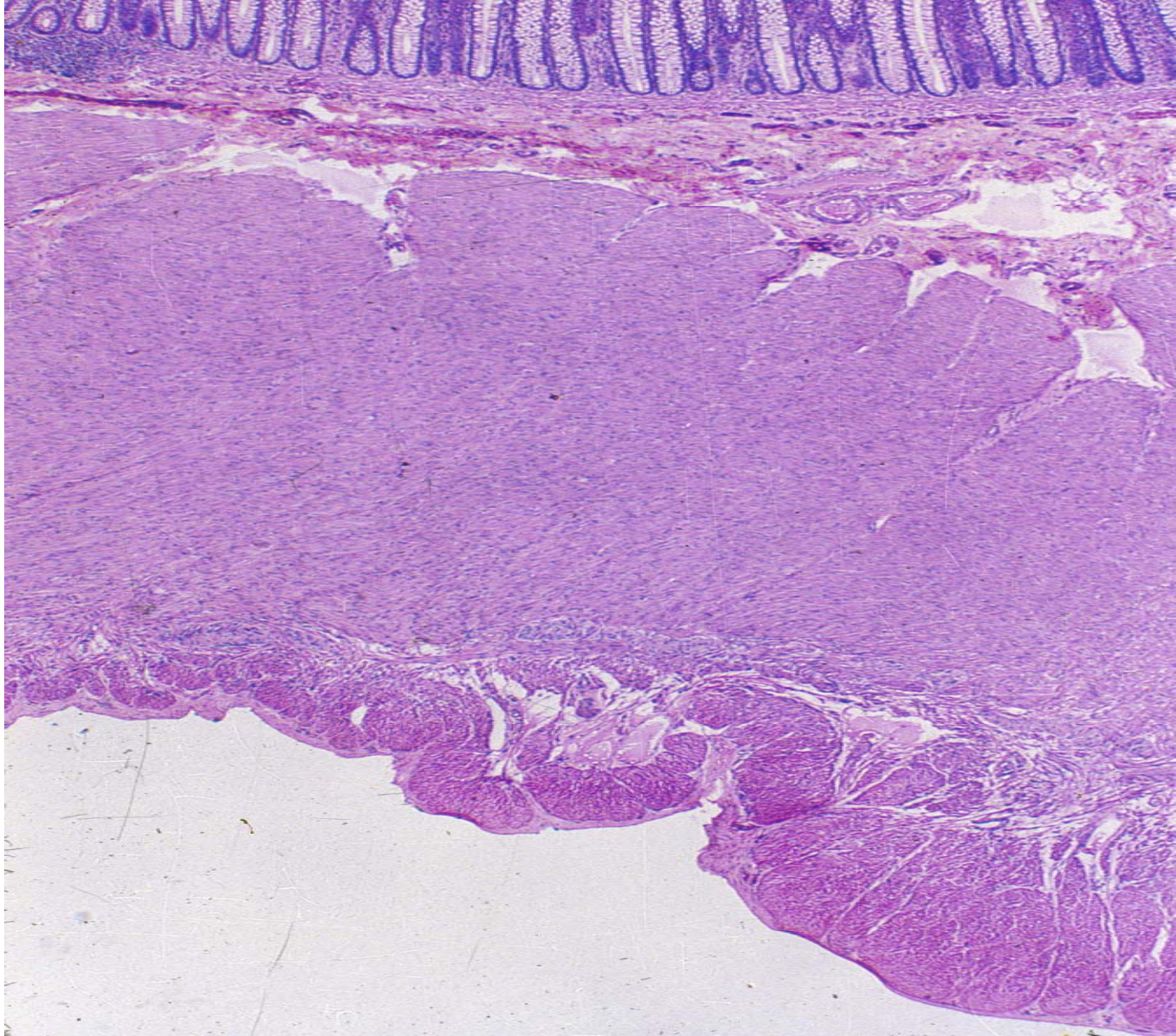
ileum



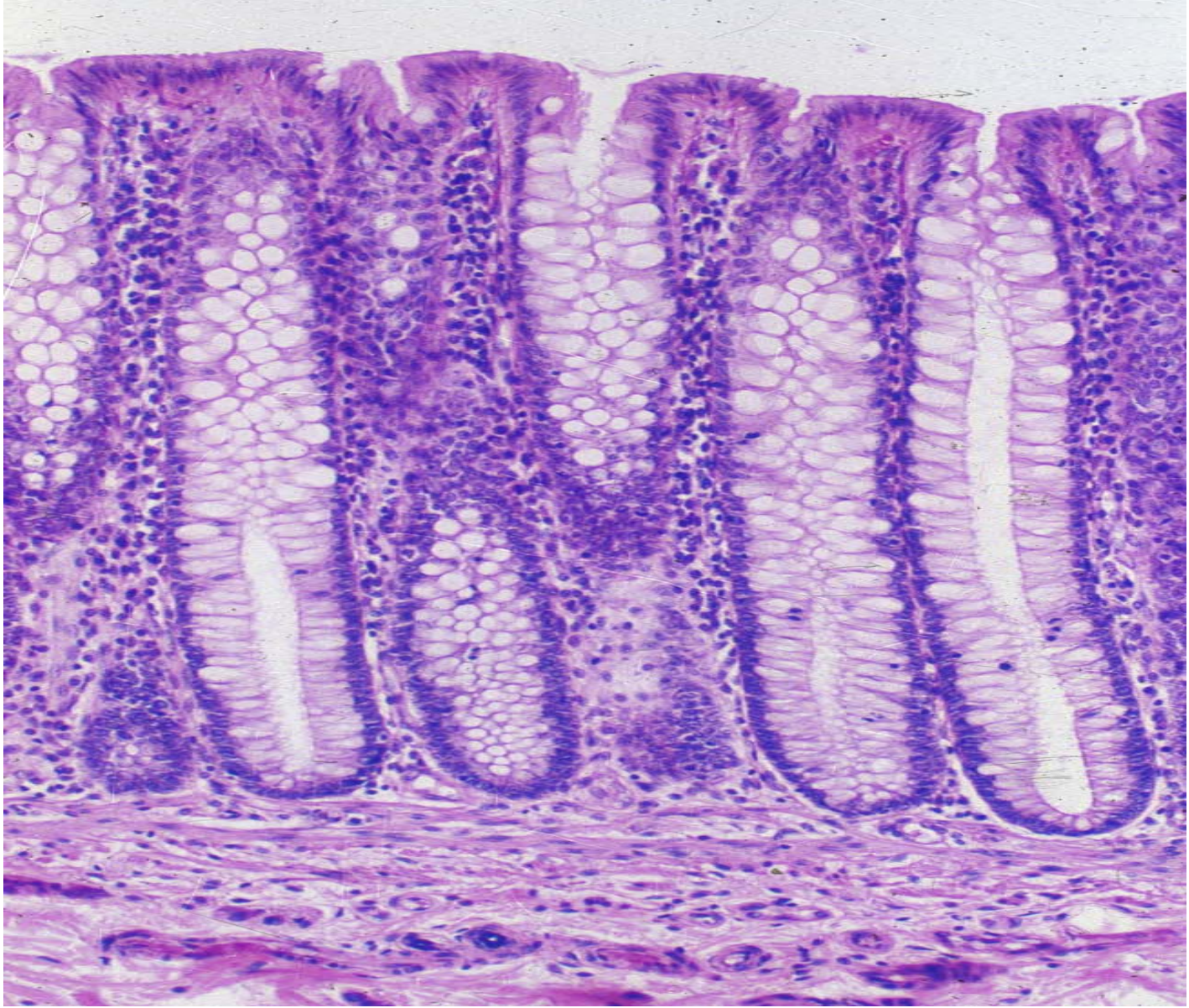Goblet cell



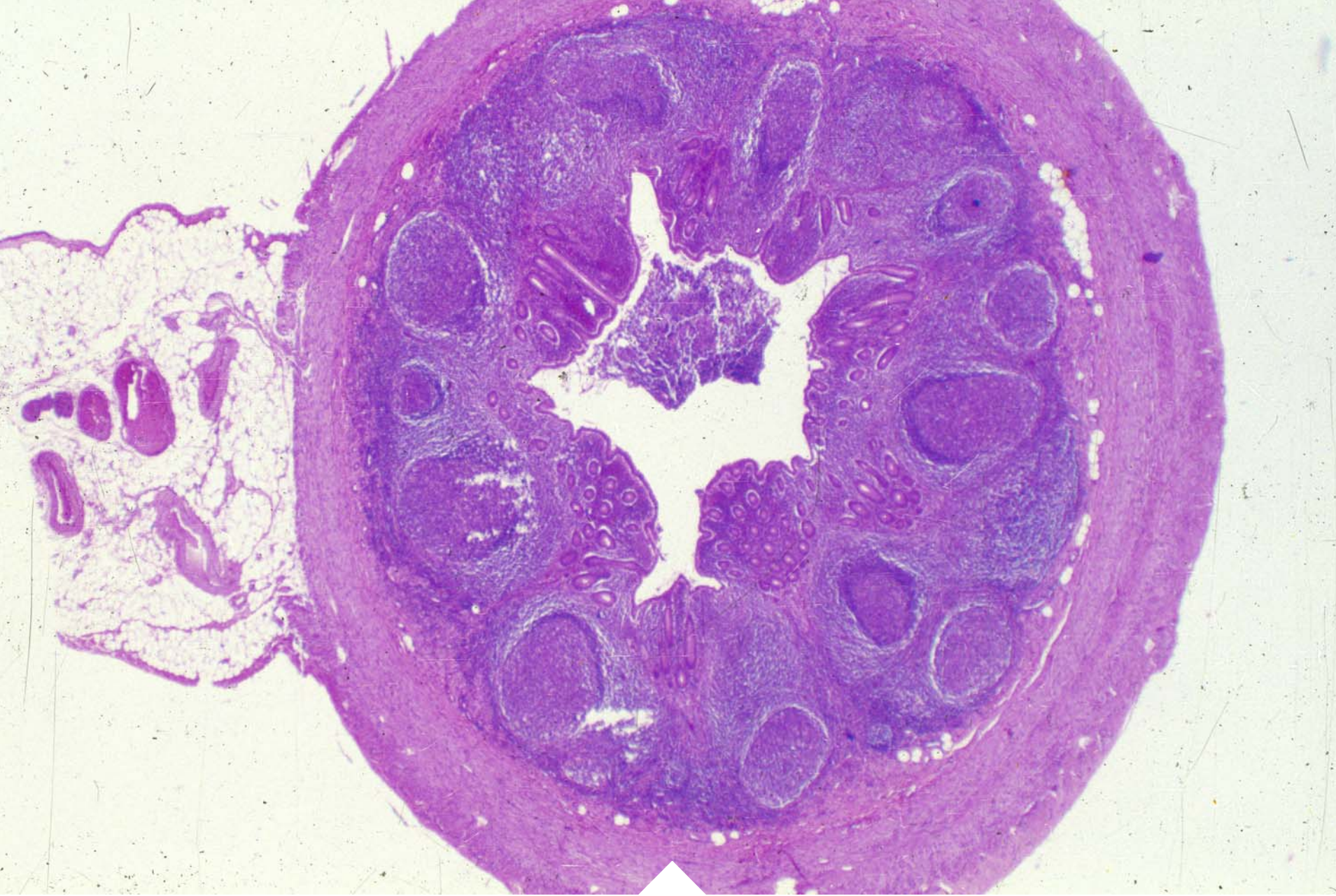Myenteric nerve plexus



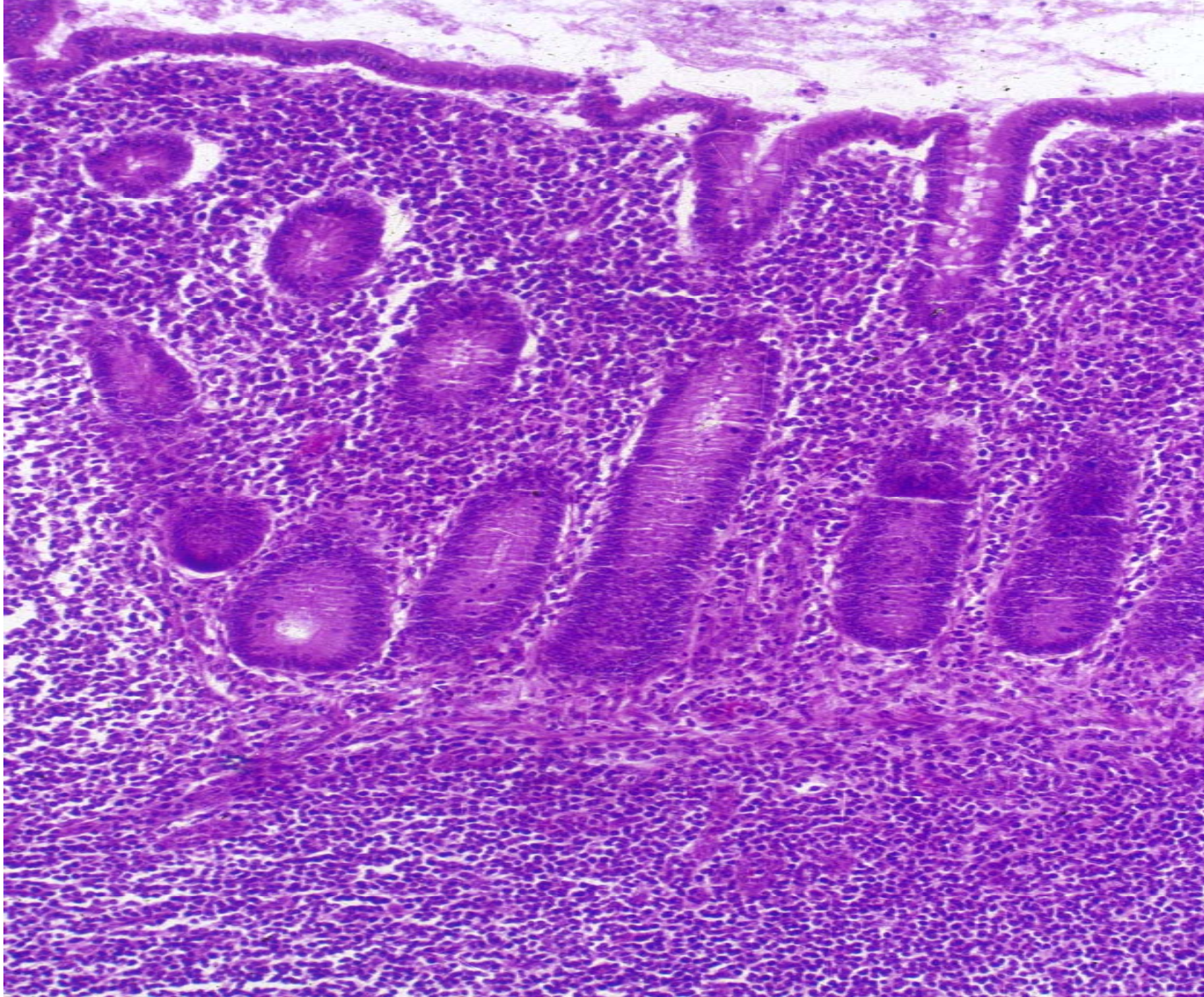
Teniae coli



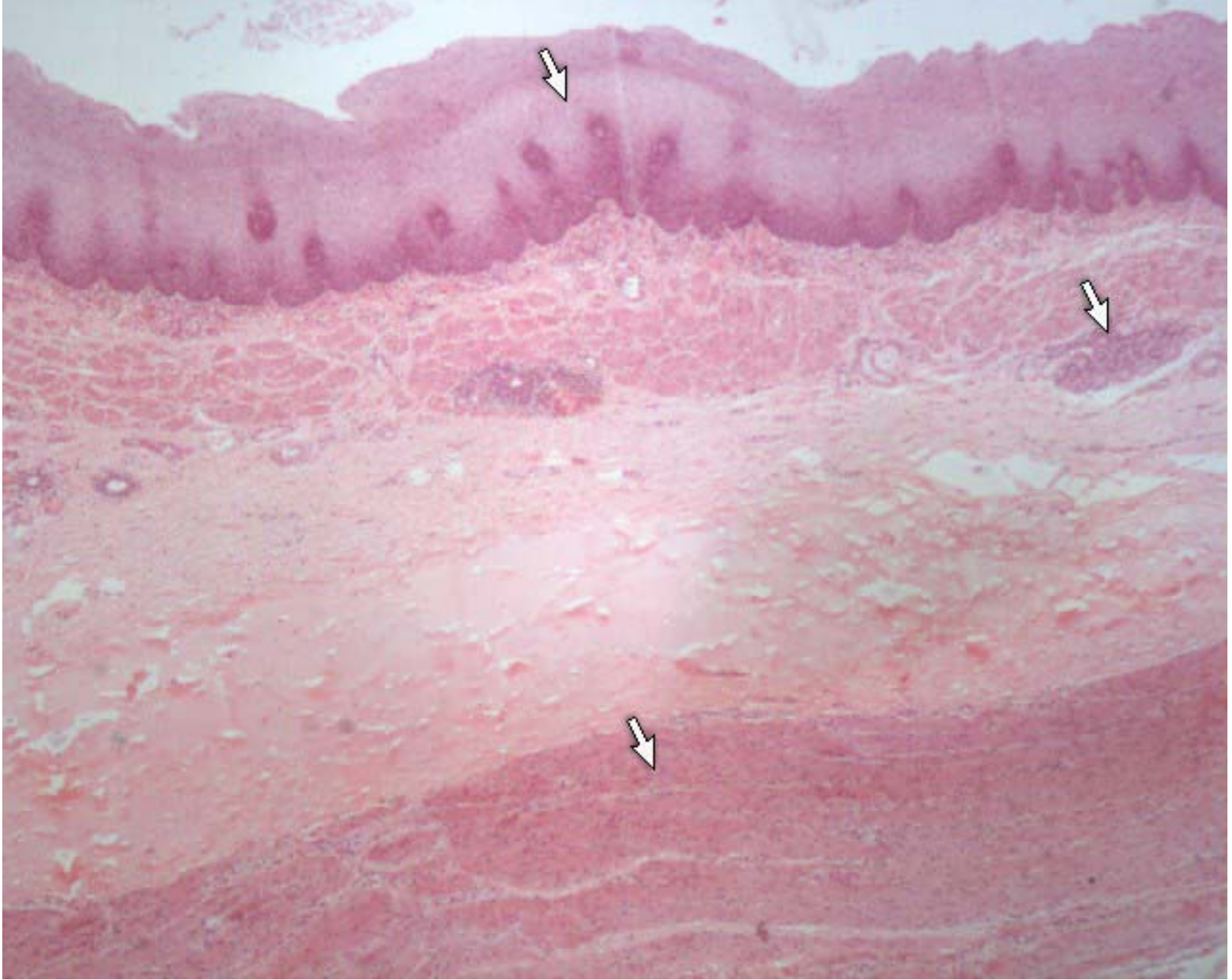
Coli gland



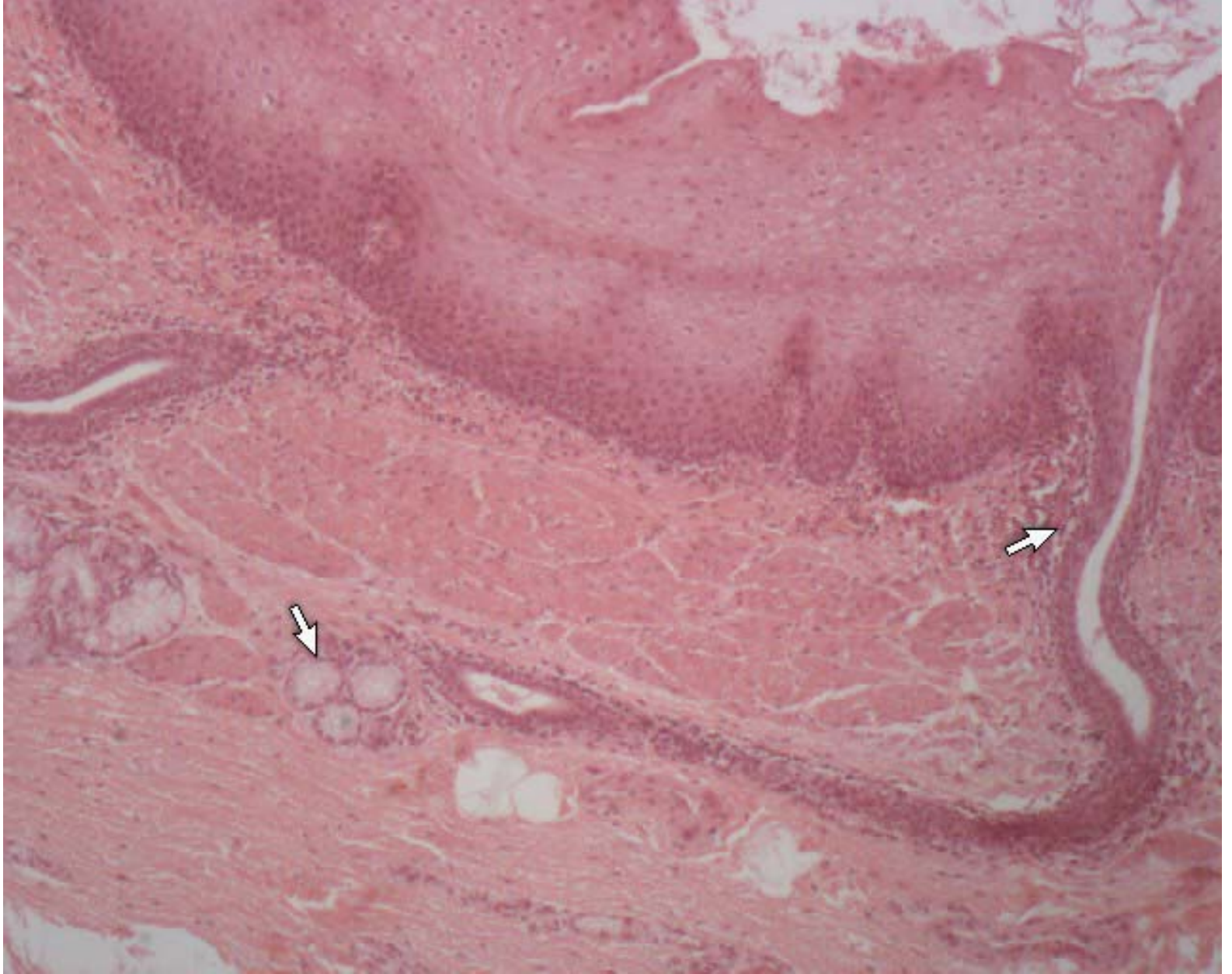
appendix



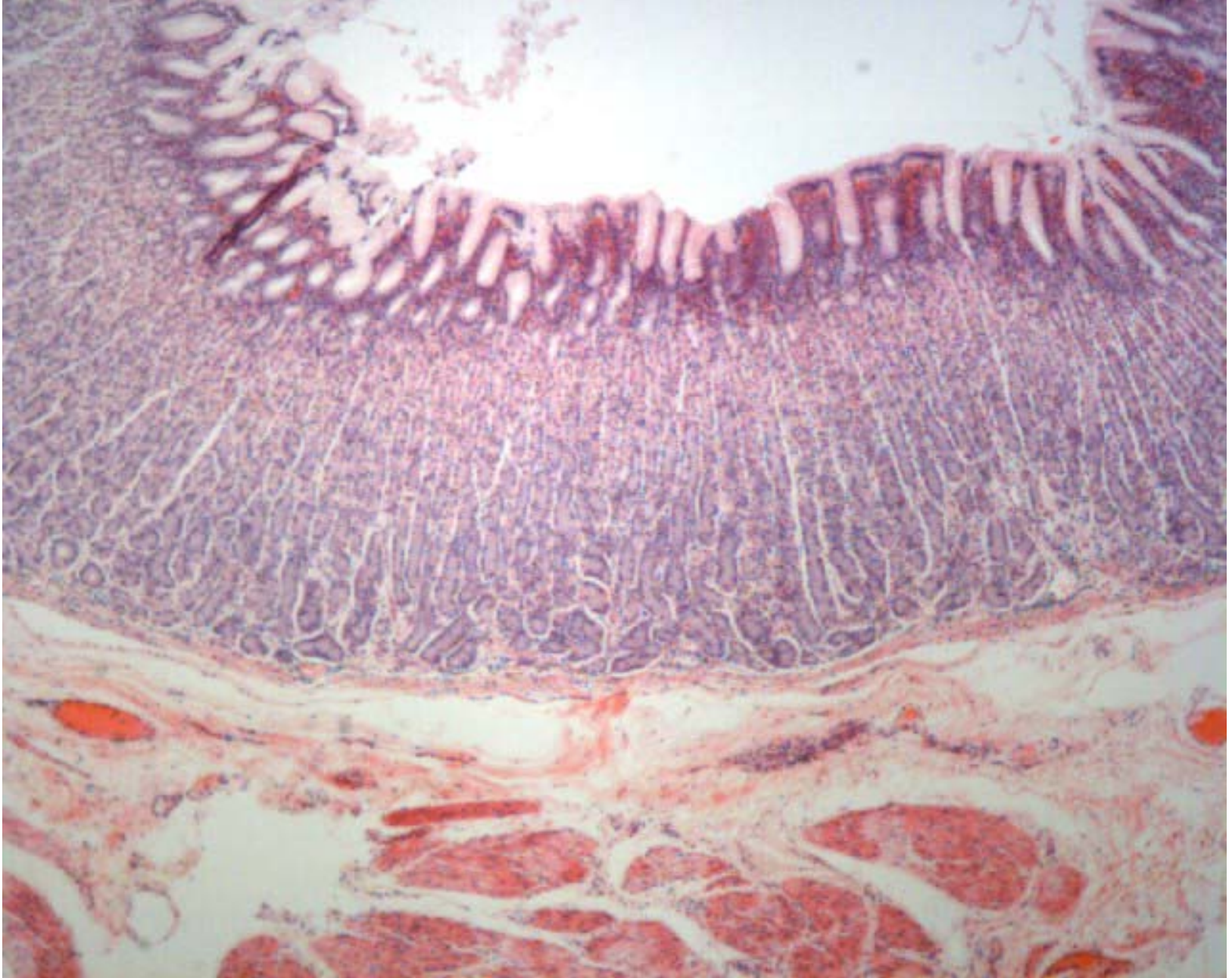
appendix



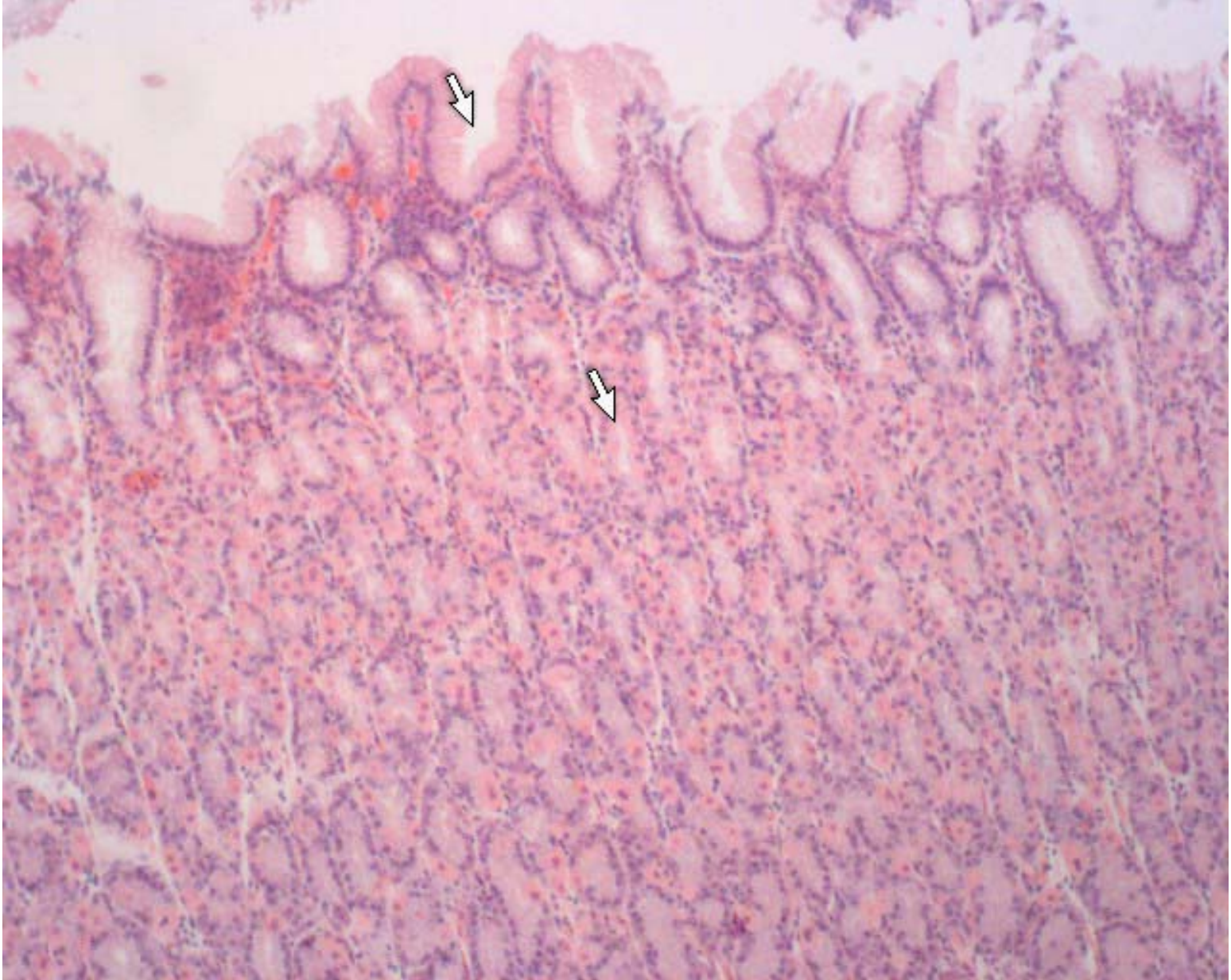
esophagus



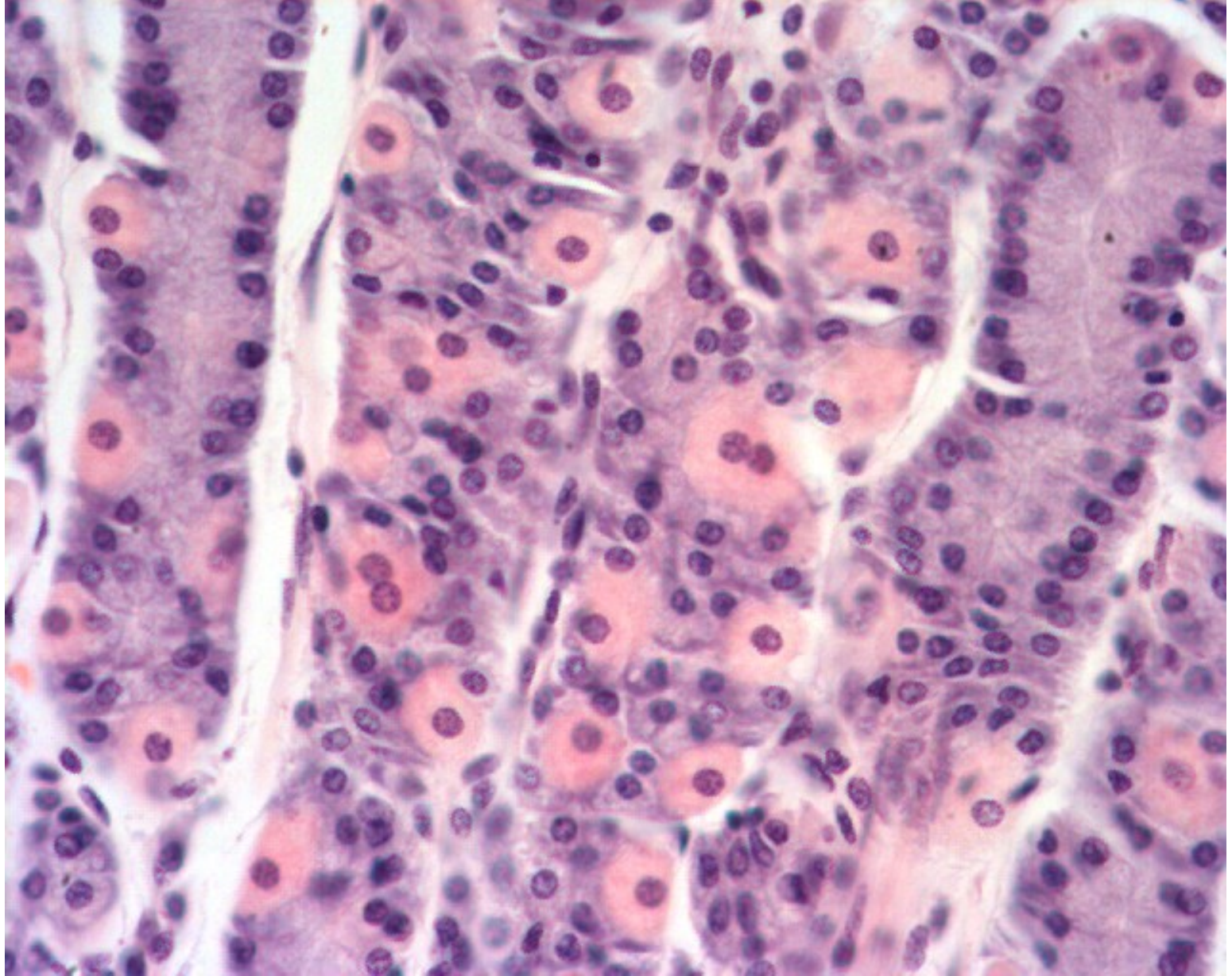
esophagus



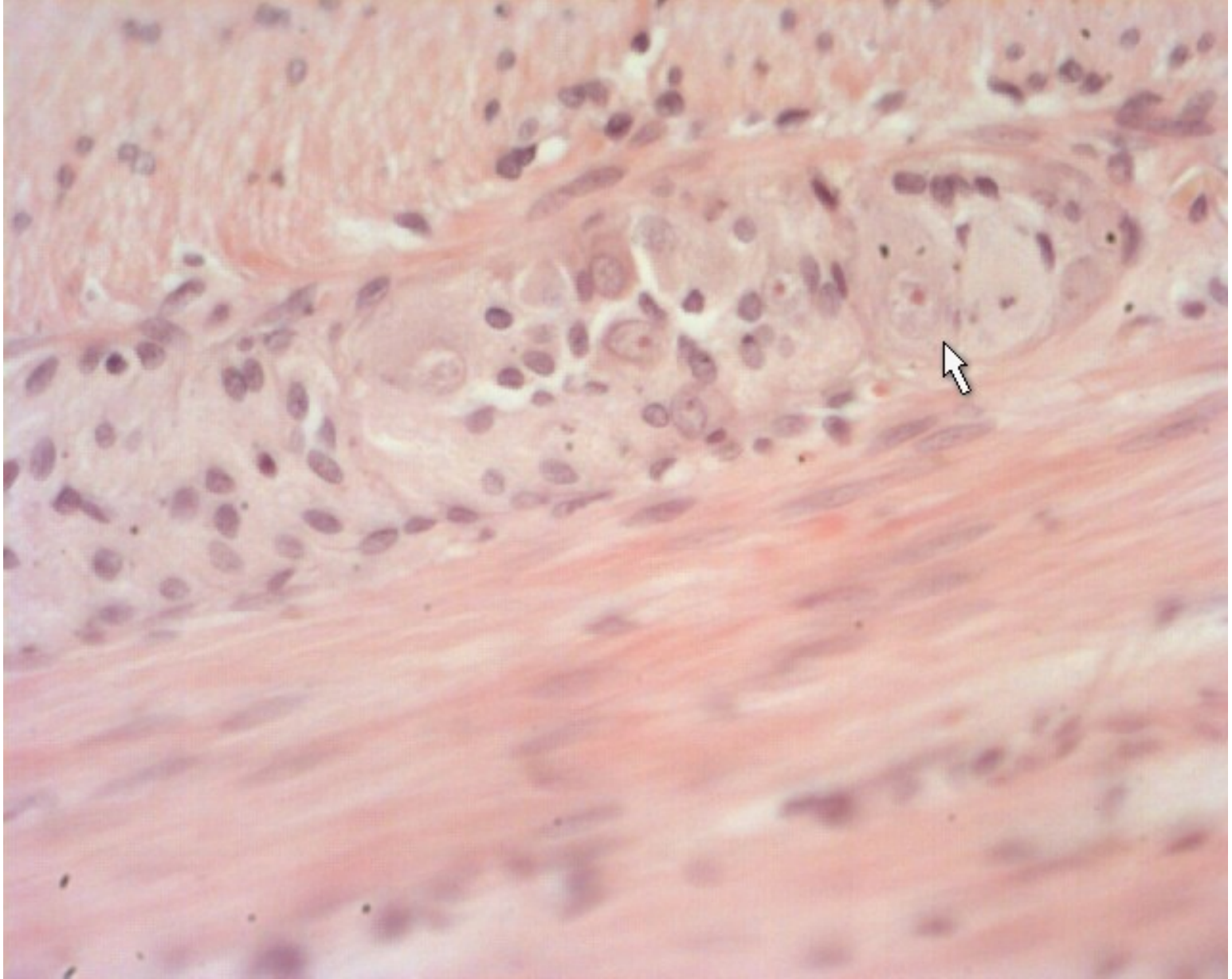
stomach



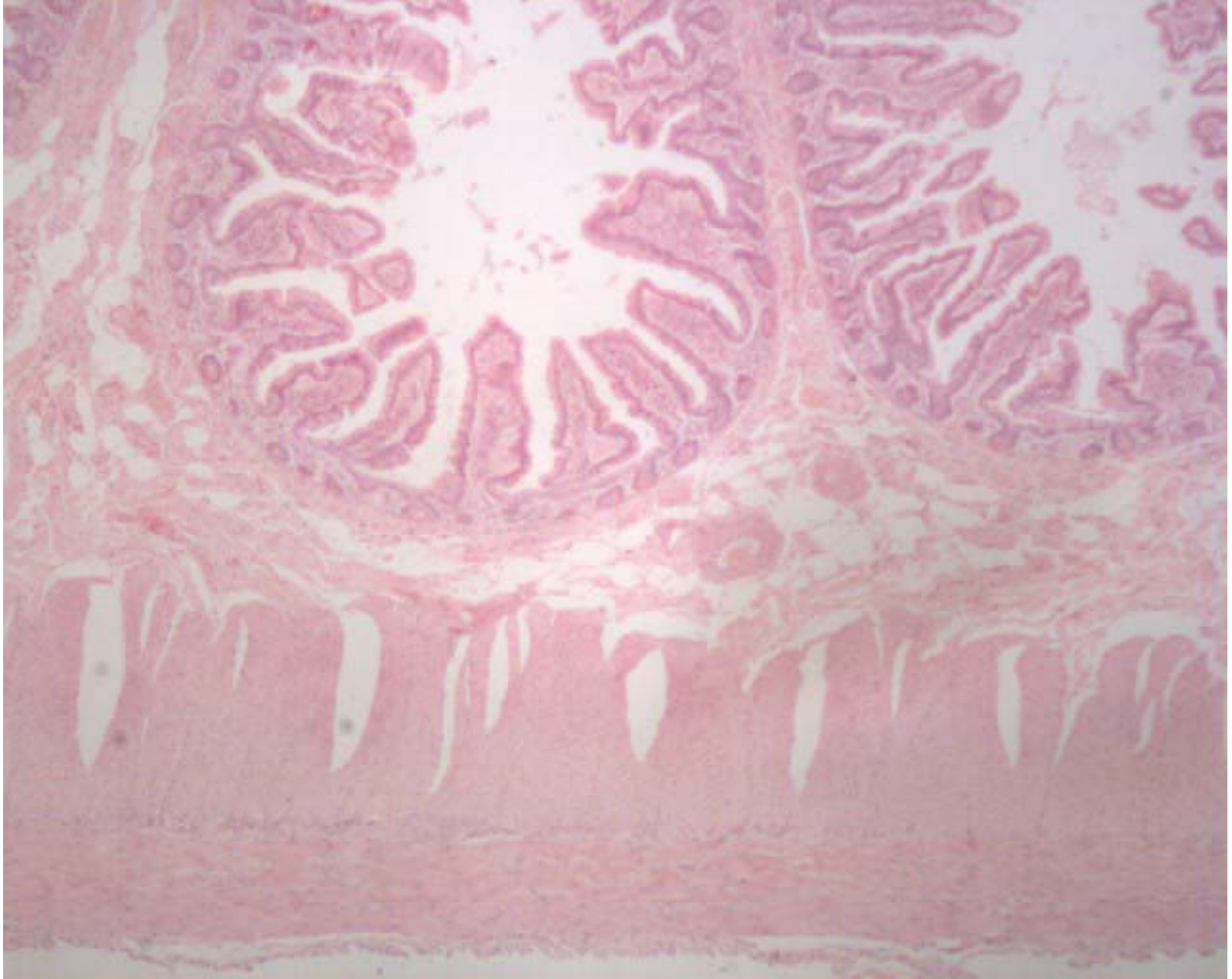
Fundic gland



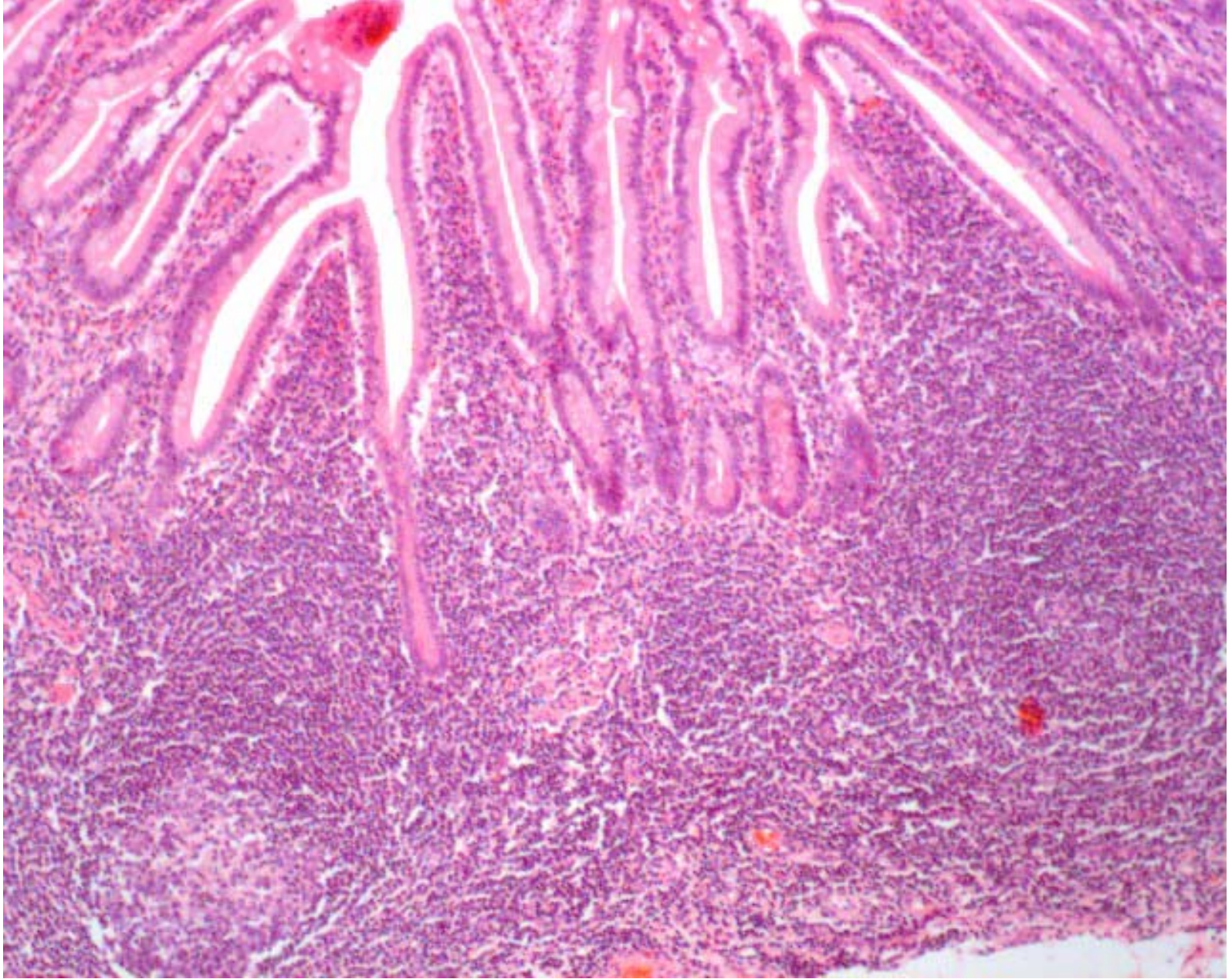
Fundic gland



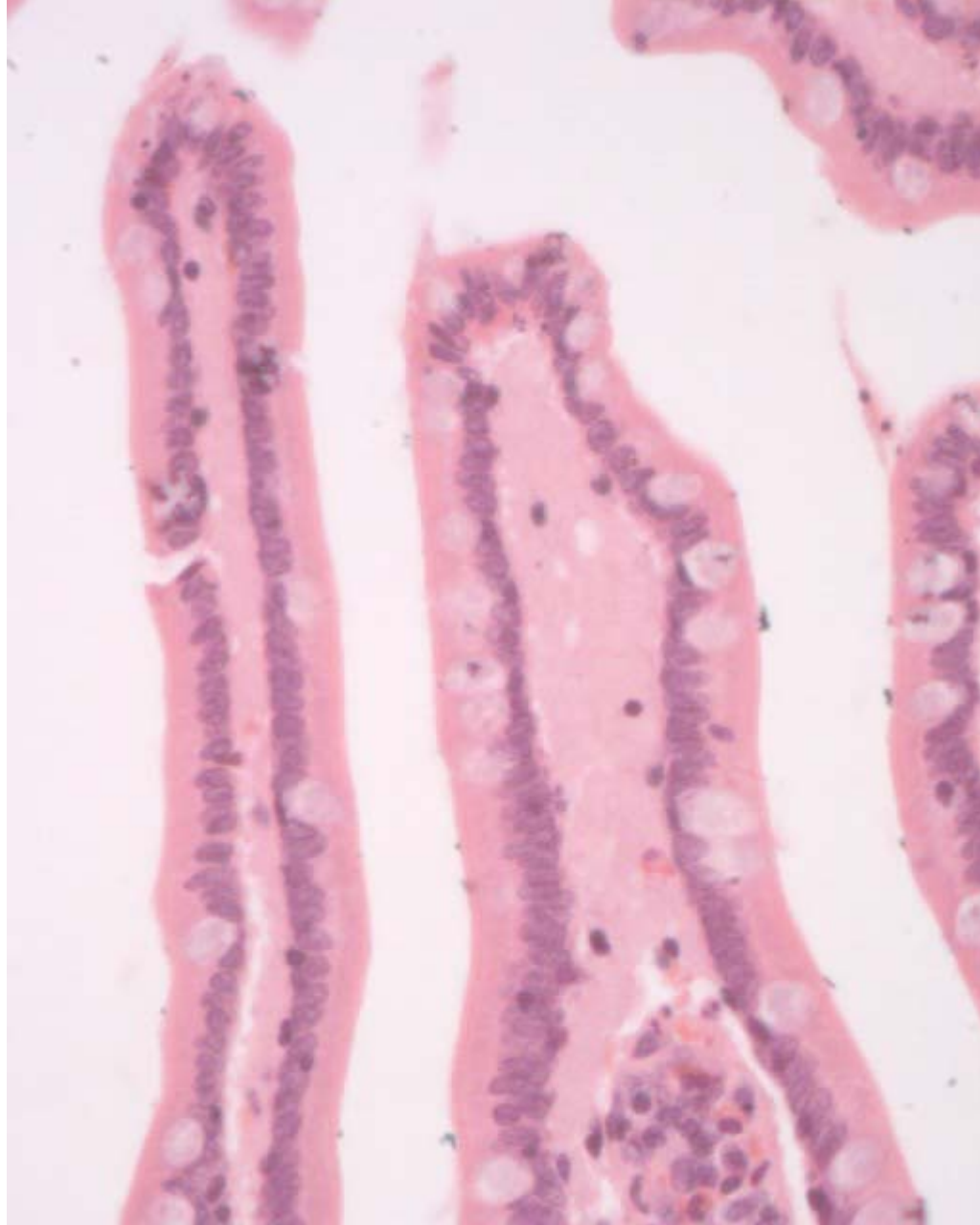
Myenteric nerve plexus



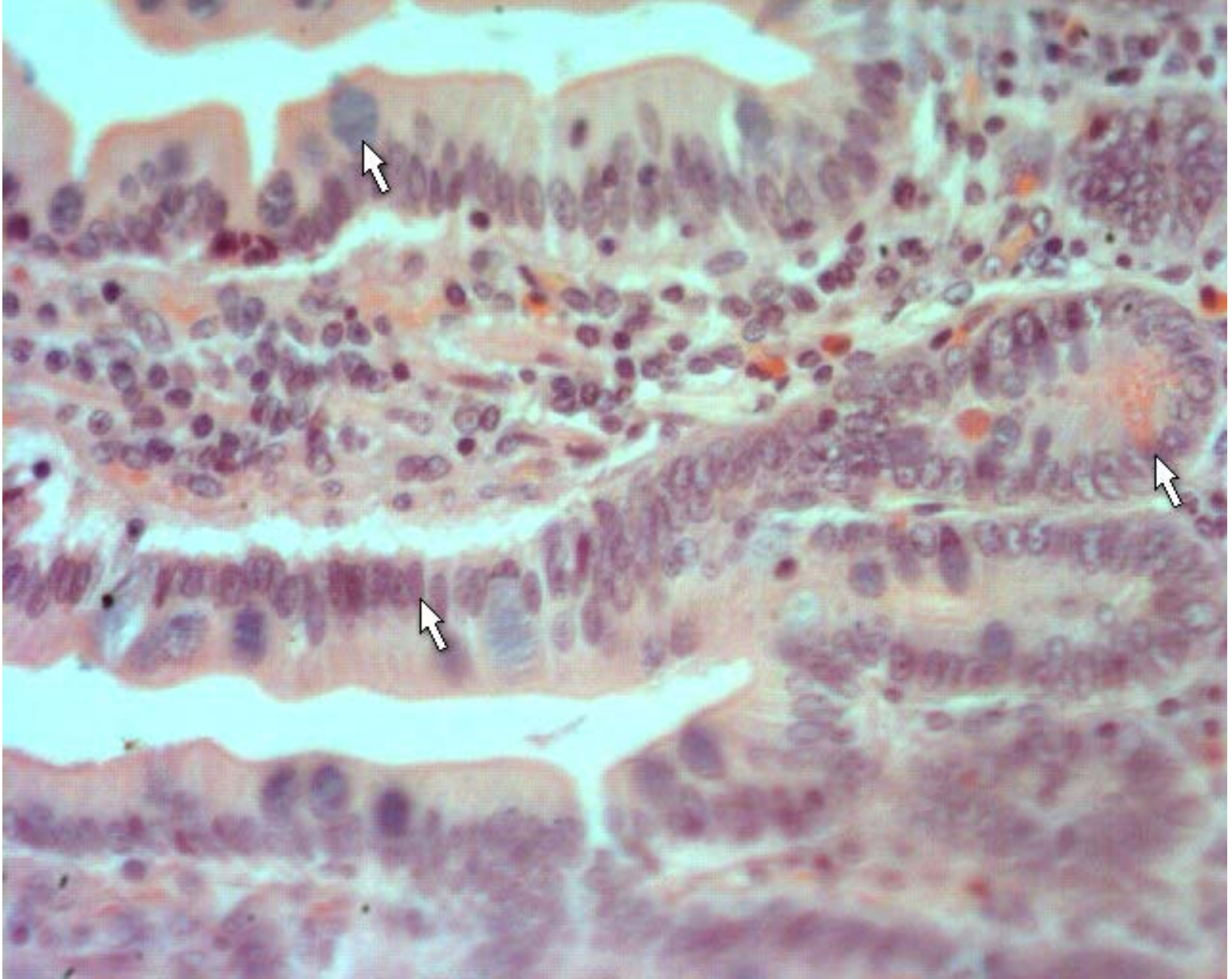
Small intestine



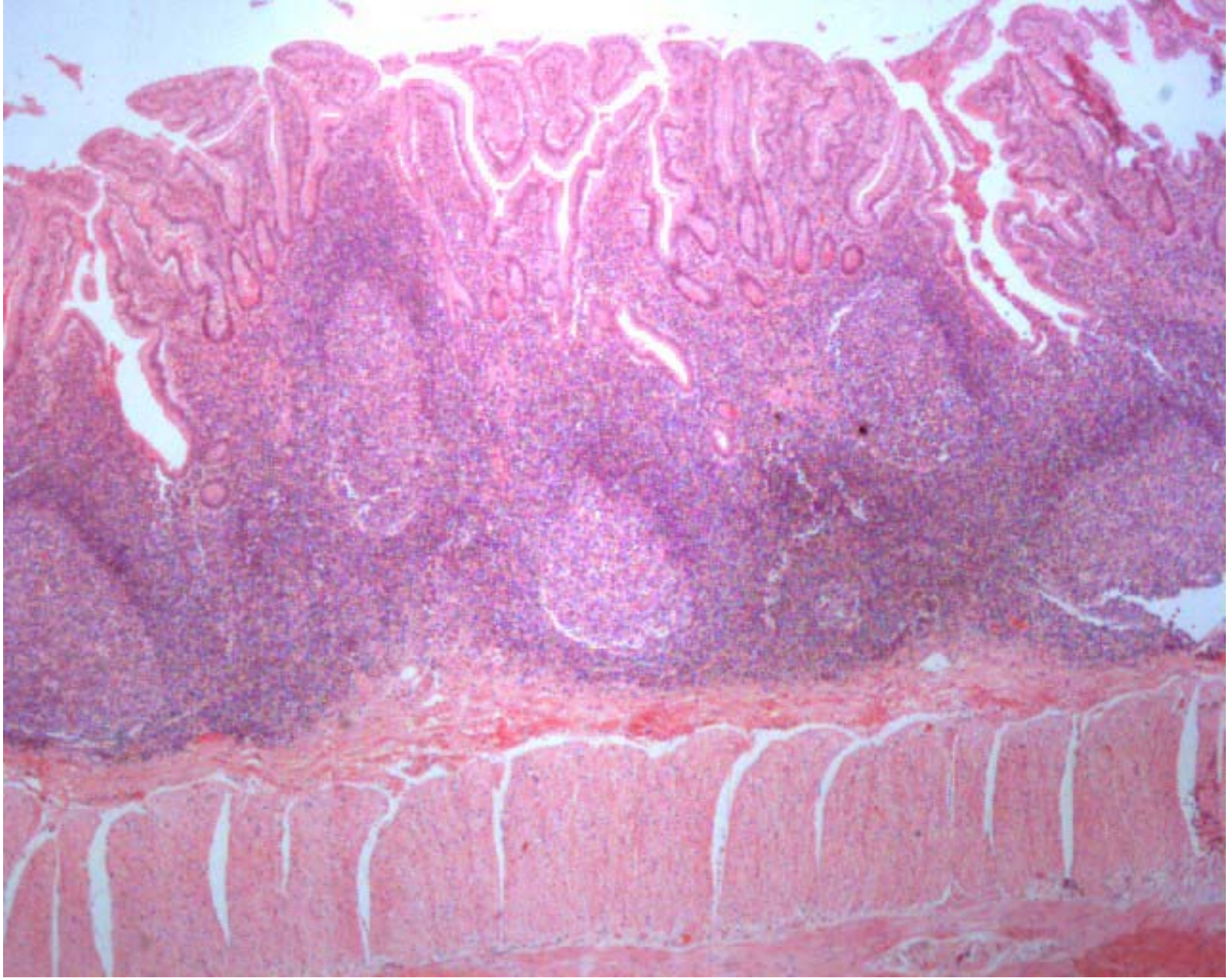
ileum



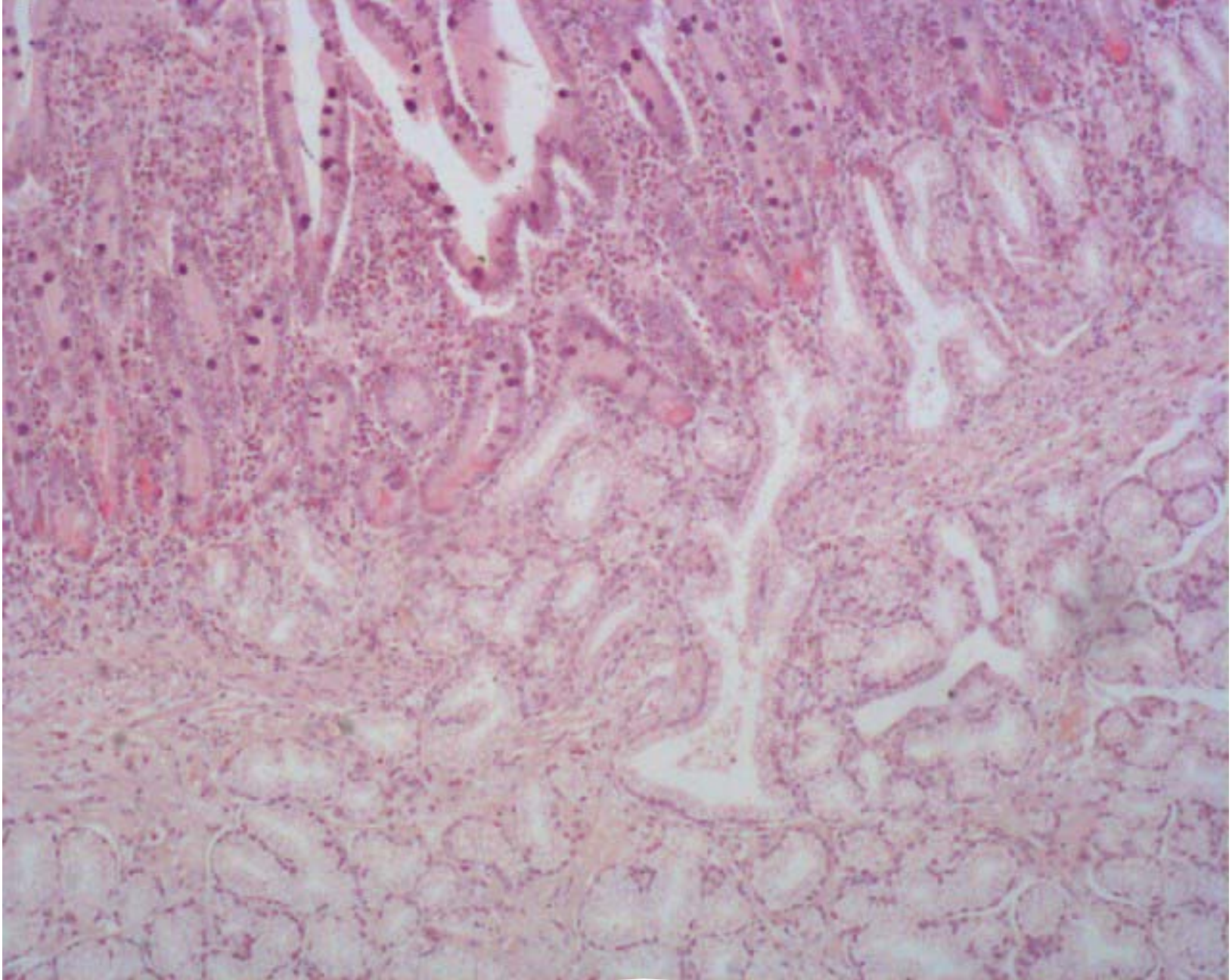
Intestinal villus



Intestinal villus

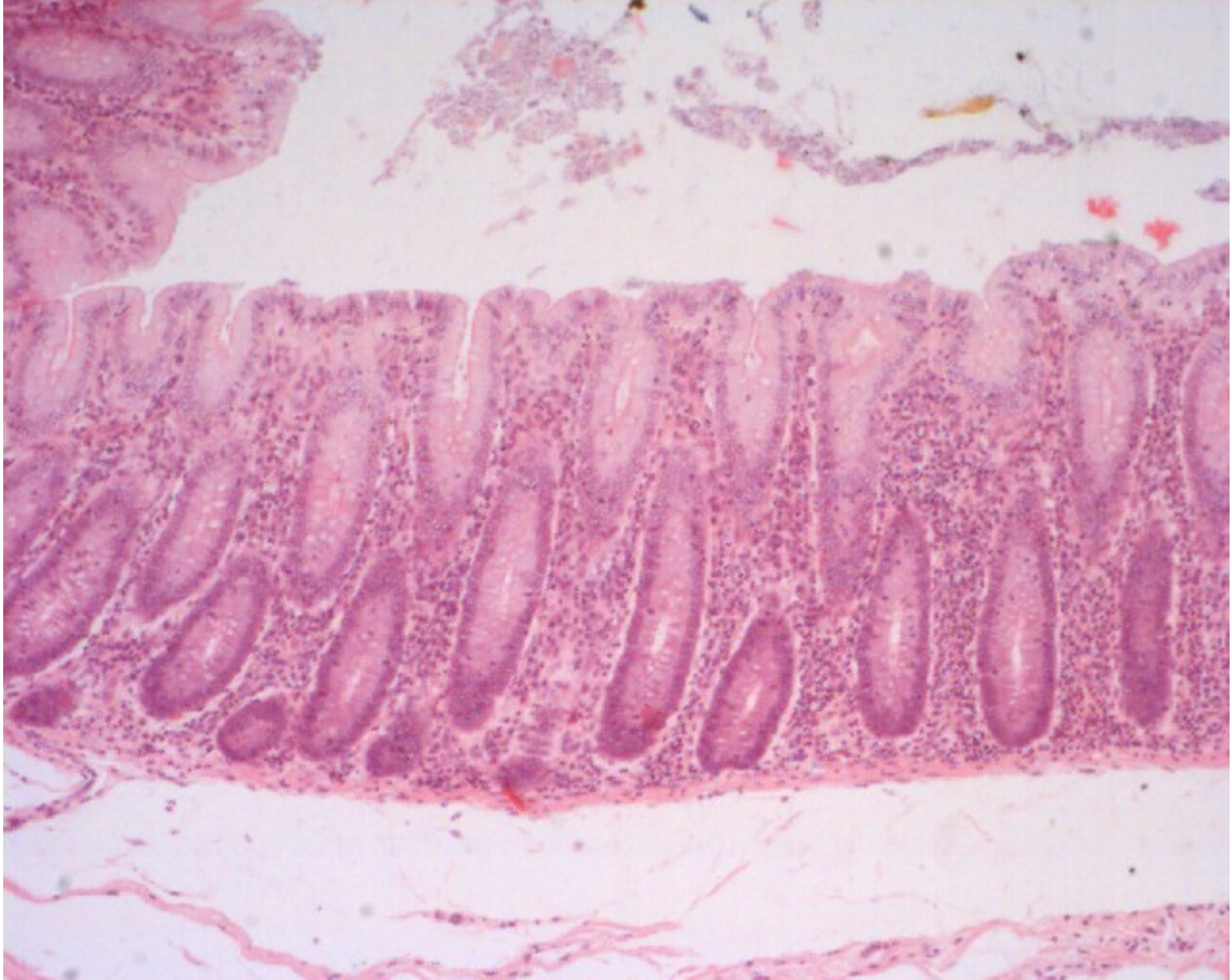

ileum



Duodenal

1. 1



Coli gland